Pediatric Dentistry

Dental trauma

Selena Hariharan, MD thank you to:
Laura Doss, DDS
CCHMC

Primary Teeth

Upper teeth

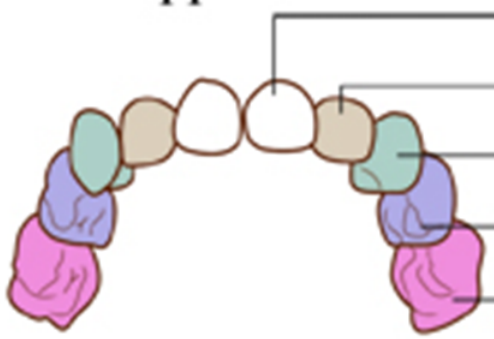

	Age tooth comes in	Age tooth falls out
Central incisor	8-12 mos.	6-7 yrs.
Lateral incisor	9-13 mos.	7-8 yrs.
Canine (cuspid)	16-22 mos.	10-12 yrs.
First molar	13-19 mos.	9-11 yrs.
Second molar	25-33 mos.	10-12 yrs.

Lower teeth

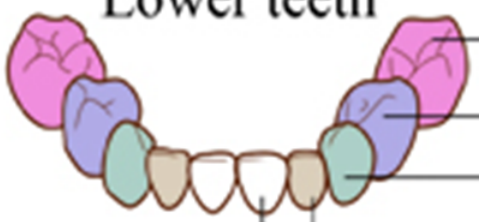

Second molar	23-31 mos.	10-12 yrs.
First molar	14-18 mos.	9-11 yrs.
Canine (cuspid)	17-23 mos.	9-12 yrs.
Lateral incisor	10-16 mos.	7-8 yrs.
Central incisor	6-10 mos.	6-7 yrs.

Eruption Times

Eruption times for primary and permanent teeth [34]

	Primary teeth							
	Central incisor	Lateral incisor	Canine	First premolar	Second premolar	First molar	Second molar	Third molar
Maxillary teeth	10 mo	11 mo	19 mo			16 mo	29 mo	
Mandibular teeth	8 mo	13 mo	20 mo			16 mo	27 mo	
	Permanent teeth							
	Central incisor	Lateral incisor	Canine	First premolar	Second premolar	First molar	Second molar	Third molar
Maxillary teeth	7–8 yr	8–9 yr	11–12 yr	10–11 yr	10–12 yr	6–7 yr	12–13 yr	17–21 yr
Mandibular teeth	6–7 yr	7–8 yr	9–10 yr	10–12 yr	11–12 yr	6–7 yr	11–13 yr	17–21 yr

Resources

- Best resource for dental traumas:
  - www.dentaltraumaguide.org

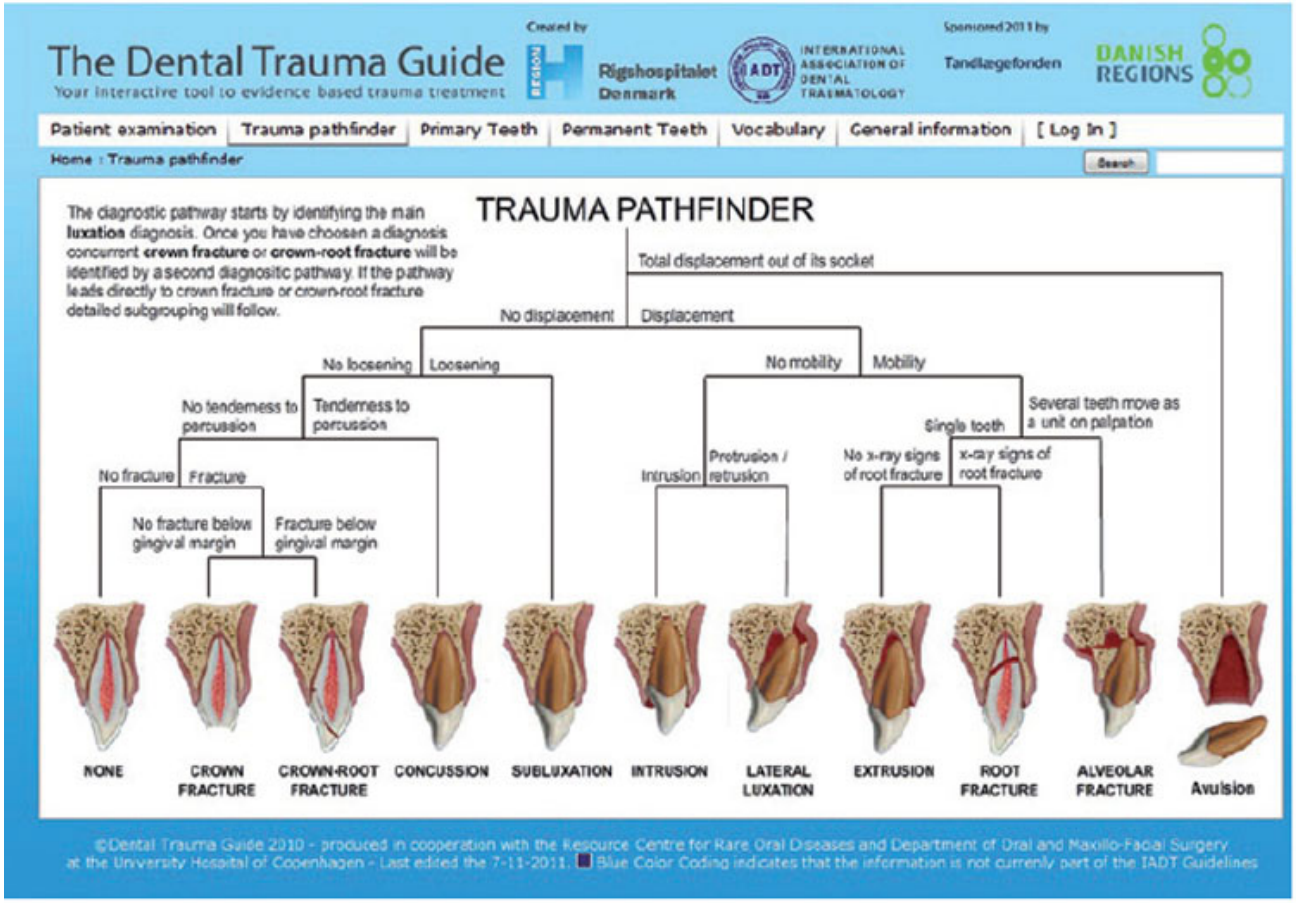

NOTE THAT TREATMENTS AND FOLLOWUP RECOMMENDATIONS VARY FROM PRIMARY TO PERMANENT TEETH !

Subluxation

Subluxation- Injury to tooth-supporting structures with abnormal loosening but without tooth displacement. PDL absorbs injury, clinical findings reveal mobile tooth without displacement.

Description:

- "Hit the tooth on…"
- Slight mobility
- No true displacement
- Bleeding from gingival sulcus present
- Percussion sensitivity is present
- Potential tooth discoloration, pulpal calcification
- Potential pathologic resorption
- May see widened PDL on radiograph initially

Subluxation: Treatment

Subluxation of primary teeth	
Treatment	Soft diet, observation, avoid cold and excessive incising Optimize healing of PDL and maintain pulpal vitality
Prognosis	Tooth should be followed for pathology If healthy, primary tooth should be normal within 2 weeks

Subluxation of permanent teeth	
Treatment	Soft diet, observation, avoid cold and excessive incising Optimize healing of PDL and maintain pulpal vitality
Prognosis	Stabilize the tooth and relieve and occlusal interference. Splint if necessary for no more than 2 weeks. Mature permanent teeth with closed apices may undergo pulpal necrosis due to associated injuries at apex and, therefore, must be followed carefully

- **Does not** need to be seen by dental resident emergently

- Patient should **follow up** with CCHMC dental or private dentist the **next day** for clinical and radiographic evaluation

Lateral Luxation

Lateral Luxation- Displacement of a tooth in a direction other than axially. PDL is torn and a contusion or fracture of the supporting alveolar bone occurs. Clinically, tooth is displaced with crown usually in a palatal or lingual direction and may be locked in this position. Usually the tooth is not extremely mobile and is tender to touch. Radiographic exam shows an increase in PDL space and displacement of apex toward or through the labial bone plate.

Description:

- Lateral displacement of a tooth, mesio-distal or bucco-lingual
- PDL compressed/ torn
- Pulp blood supply/ innervations can be severed
- Associated fracture of cortical plate possible
- PDL compression can lead to resorption

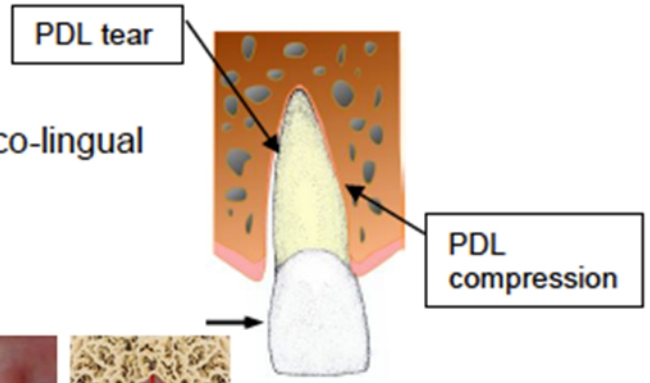

Lateral Luxation: Treatment

Lateral luxation of primary teeth	
Treatment	Goal is to allow passive of spontaneous repositioning if there is no occlusal interference (e.g.: palatal luxation of a maxillary incisor). If there is minor occlusal interference, the tooth can be gently repositioned or slightly reduced. If injury is severe, or tooth is near exfoliation, extraction is the treatment of choice because attempts to reposition can damage underlying developing teeth (approx 2.5mm from primary root tip to perm. tooth)
Prognosis	Primary teeth requiring repositioning run increased risk of pulpal necrosis relative to those that spontaneously reposition.

Lateral luxation of permanent teeth	
Treatment	Reposition as soon as possible, may need to be extruded to free itself from the apical lock in cortical bone plate. Stabilize tooth in its correct anatomical position to optimize PDL healing and neurovascular supply. Non-rigid splint for 3-4 weeks (allow healing of marginal bone) If open apices → Possible revascularization If closed apices → RCT*
Prognosis	Guarded, in mature permanent teeth with closed apices, pulp necrosis and pulp canal obliteration are common healing complications. Pathologic resorption can occur due to compression of PDL

- **ALL** primary and permanent **luxations** should be **seen emergently** by dental resident on call

Intrusive Luxation

Intrusive Luxation- Apical displacement of the tooth into the alveolar bone. Tooth is driven into the socket, compressing the PDL and commonly causing a crushing fracture of the alveolar socket.

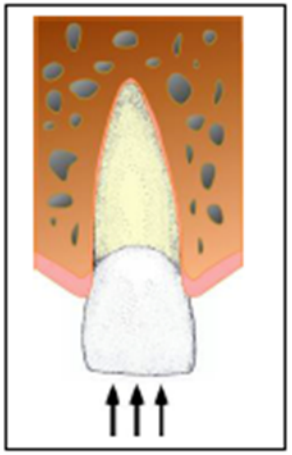

Description

- Apical displacement of a tooth
- Tooth appears to be shortened
- In severe cases, tooth may appear to be missing
- Not mobile, driven into alveolar process or labial bone
- Radiographically, root appears displaced apically and PDL space is not continuous.

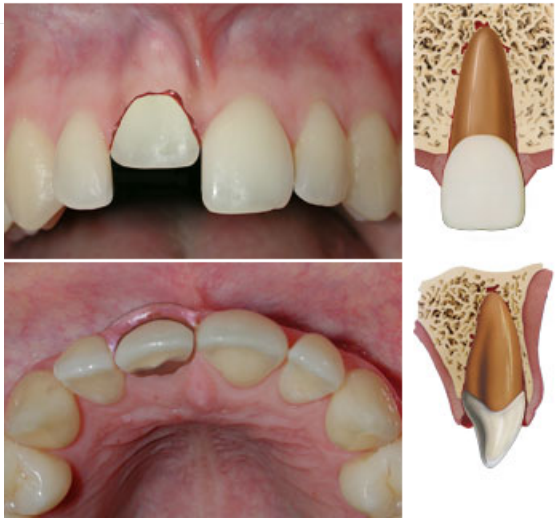

Intrusive Luxation: Treatment

Intrusion of primary teeth	
Treatment	Observation Allow spontaneous re-eruption except when displaced into developing successor Extraction may be indicated when apex is displaced toward developing permanent tooth.
Prognosis	90% will re-erupt spontaneously (either partially or completely) in 2 to 6 months Ankylosis may occur if severe PDL damage is present May discolor May not remain vital and abscess May damage underlying developing teeth

Intrusion of permanent teeth	
Treatment	Reposition • Passively- allowing re-eruption to its correct position • Actively - reposition with traction • Surgically Stabilize with a splint for up to 4 weeks in anatomically correct position Incomplete root formation (Immature tooth/ open apex) • Loosen, observe and wait for re-eruption • Possible revascularization Complete root formation (Mature tooth/ closed apex) • Orthodontically / surgically reposition • RCT should be initiated within 3 weeks of the traumatic incident
Prognosis	In mature permanent teeth with closed apices, there is considerable risk for pulp necrosis, pulp canal obliteration, and pathologic root resorption. Immature teeth that are allowed to reposition spontaneously have lowest risk of healing complications Extent of intrusion (7mm or greater) and adjacent intruded teeth have a negative effect on healing Pulpal necrosis frequent Pathologic root resorption common complication seen as late as 5-20 years later, thus radiographic monitoring is appropriate.

- **ALL** primary and permanent **luxations** should be **seen emergently** by dental resident on call

Avulsion

- **Avulsion -** Tooth is completely displaced out of its socket. Socket is found completely empty or filled with coagulum

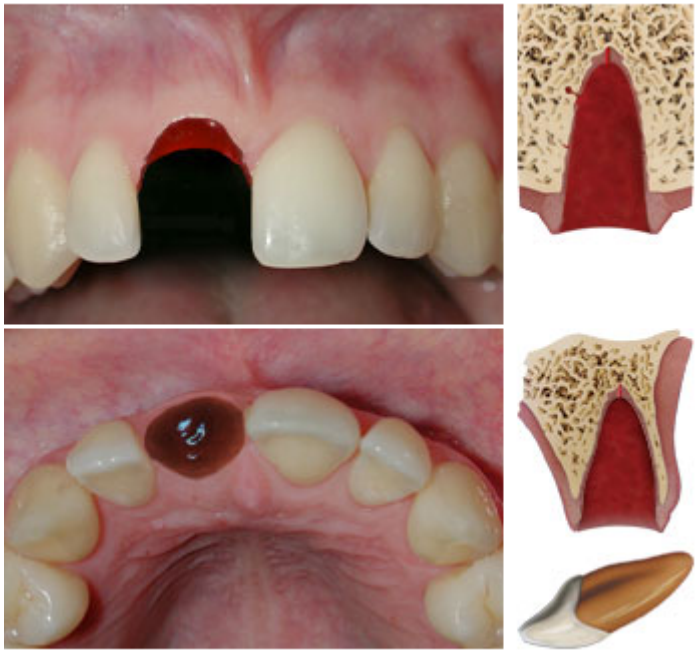

Avulsion: Treatment

Avulsion of primary teeth	
Treatment	**DO NOT REIMPLANT** Potential for subsequent damage to developing permanent tooth
Prognosis	Good

Avulsion of permanent teeth	
Treatment	**REIMPLANT IMMEDIATELY** Time out of the mouth is critical Keep tooth hydrated to maintain PDL cell vitality, "Save a tooth" kit is best Once re-implanted, non-rigid splint is placed for 2 weeks Systemic antibiotics and tetanus prophylaxis should be considered 7 – 10 day follow up required
Prognosis	Guarded prognosis, generally dependent on level on root development and dry time Tooth has best prognosis if re-implanted immediately Risk of ankyloses increased significantly with extra oral dry time of 20 minutes Extra oral dry time over 60 minutes, survival of PDL cells is unlikely

- **ALL** primary and permanent tooth **avulsions** should be **seen emergently** by dental resident on call

Fractures

- Uncomplicated fracture
  - Ellis Class I or II fractures
  - Involves enamel/dentin only
  - No pulpal exposure

- Complicated fracture
  - Ellis Class III fracture
  - Enamel-dentin fracture with pulp exposure

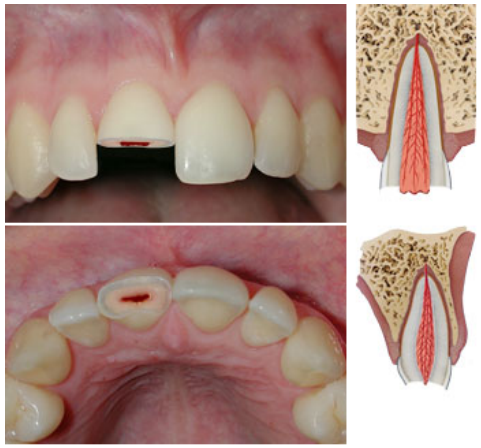

Primary tooth fracture: Treatment

- Uncomplicated fracture:
  - Emergently:
    - No treatment usually necessary
    - Smooth off sharp edges/place flowable band aid if sensitive
  - Monitor pulp vitality

- Complicated fracture:
  - Emergently:
    - Likely extract, may initiate nerve treatment
  - Monitor pulp vitality

Permanent Tooth Fracture: Treatment

- Uncomplicated fracture:
  - Emergently: flowable band aid if sensitive, look for tooth fragments in lacerations
  - Maintain pulp vitality
  - Restore to normal esthetics and tooth function

- Complicated fracture:
  - Emergently:
    - Small exposure: Direct pulp calp
    - Large exposure: Cvek
  - Monitor pulp vitality, likely initiate root canal therapy in clinic
  - Restore normal esthetics and tooth function

Odontogram

- A pictographic representation of the teeth

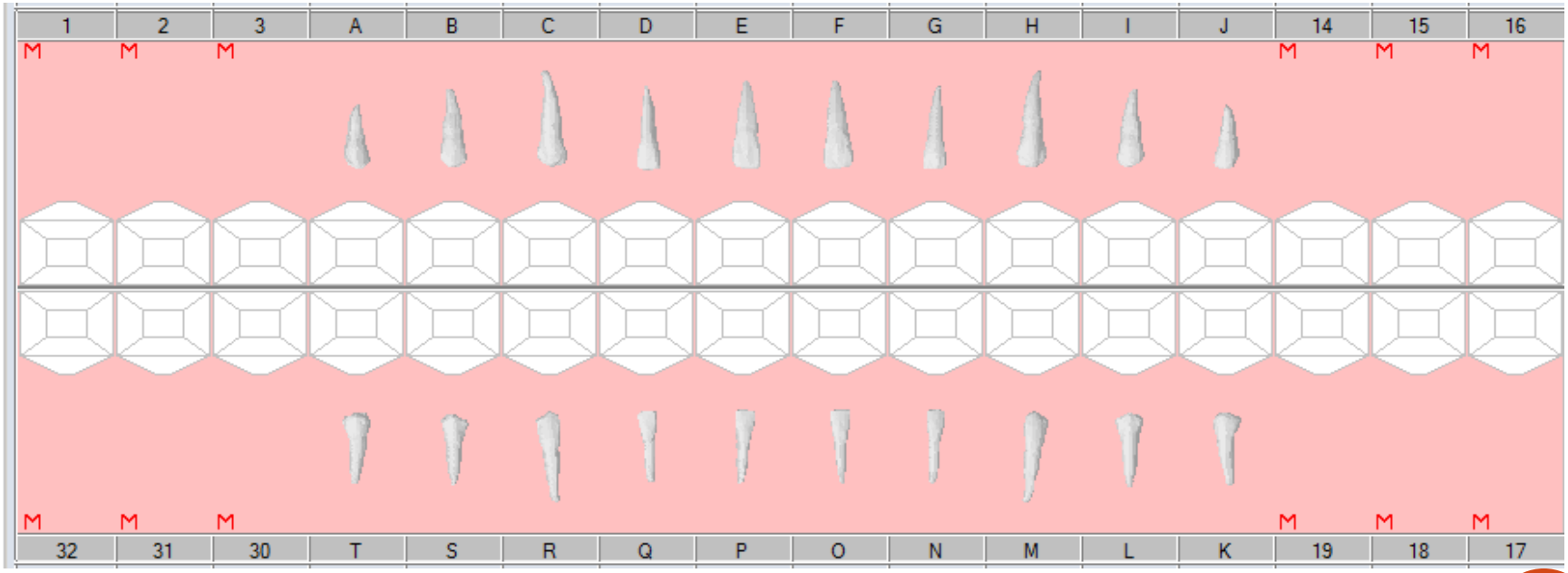

E-Brain in EPIC

- In EPIC, there is now a module in e-brain with 5 summary slides to review prior to talking to the dental resident

Process For Dental Trauma

- Evaluate the patient
- Discuss with the fellow or attending
- Consult e-brain module and www.dentaltraumaguide.org for any questions
- Call the dental resident- you will sound like an expert!
- The dental resident will ask you, the fellow or attending to sign an odntogram confirming the injury

Resources

- http://www.dentaltraumaguide.org/
- http://www.aapd.org/media/Policies_Guidelines/RS_Trauma FlowSheet.pdf