Physical Abuse

Berkeley L. Bennett M.D., M.S.

Objectives

- Discuss standardized approach to evaluation of suspected physical abuse
- Injuries concerning for abuse
- Cases that illustrate why we look for occult injuries
- Missed cases of abuse

Standardized Physical Abuse (NAT) Protocol

Why have a standardized approach?

Injuries are Missed

- Estimated that 1-15% of childhood injuries resulting in ED visits are caused by abuse.
- Up to 75% of abuse may be missed in the acute care setting because medical professionals fail to recognize signs of abuse.
- Previous sentinel injuries are identified in 25% of abused infants and in 1/3 of those with inflicted head trauma

Guidelines Reduce Bias

- Implementation of guidelines for evaluating children with suspected abuse have reduced bias based on SES
  - Decrease over-testing of lower SES groups and minorities
  - Improved identification of abuse in higher SES and “intact” families

Evaluating Physical Abuse is Hard

The guideline can help

If you are concerned AT ALL for physical abuse please use this protocol

< 6 months

- Social work consult
- Skeletal survey
- Head CT
- AST, ALT, Lipase
- Abdominal CT
  - AST or ALT ≥ 80
- Troponin I
  - AST or ALT ≥ 80
  - Signs of chest trauma
  - Ill appearance
- CBC, PT, PTT
  - Bruising
  - ICH

6-12 months

- Social work consult
- Skeletal survey
- AST, ALT, Lipase

- Abd CT
  - AST or ALT $\geq$ 80
- Troponin I
  - AST or ALT > 80
  - Signs of chest trauma
  - Ill appearance
- Head CT
  - Facial bruising
  - Abnormal neuro exam
- CBC, PT, PTT
  - Bruising
  - ICH

> 12-36 months

- Social work consult
- Skeletal survey for < 24 months
  - *Strongly consider* skeletal survey for >24-36 months if severely injured
- *Strongly consider* AST, ALT, Lipase
- Abd CT
  - AST or ALT $\geq$ 80
- Troponin I
  - AST or ALT $\geq$ 80
  - Signs of chest trauma
  - Ill appearance
- Head CT
  - Abnormal neurological exam
- CBC, PT, PTT
  - Bruising
  - ICH

Skeletal Injuries

Abusive Skeletal Injuries

- Suspicious for abuse
  - Fractures in the non-ambulatory child
  - Multiple fractures at various stages of healing
  - Specific locations
    - Posterior ribs
    - Metaphyseal corner fractures
    - Scapula, sternum, spine

Rib Fractures

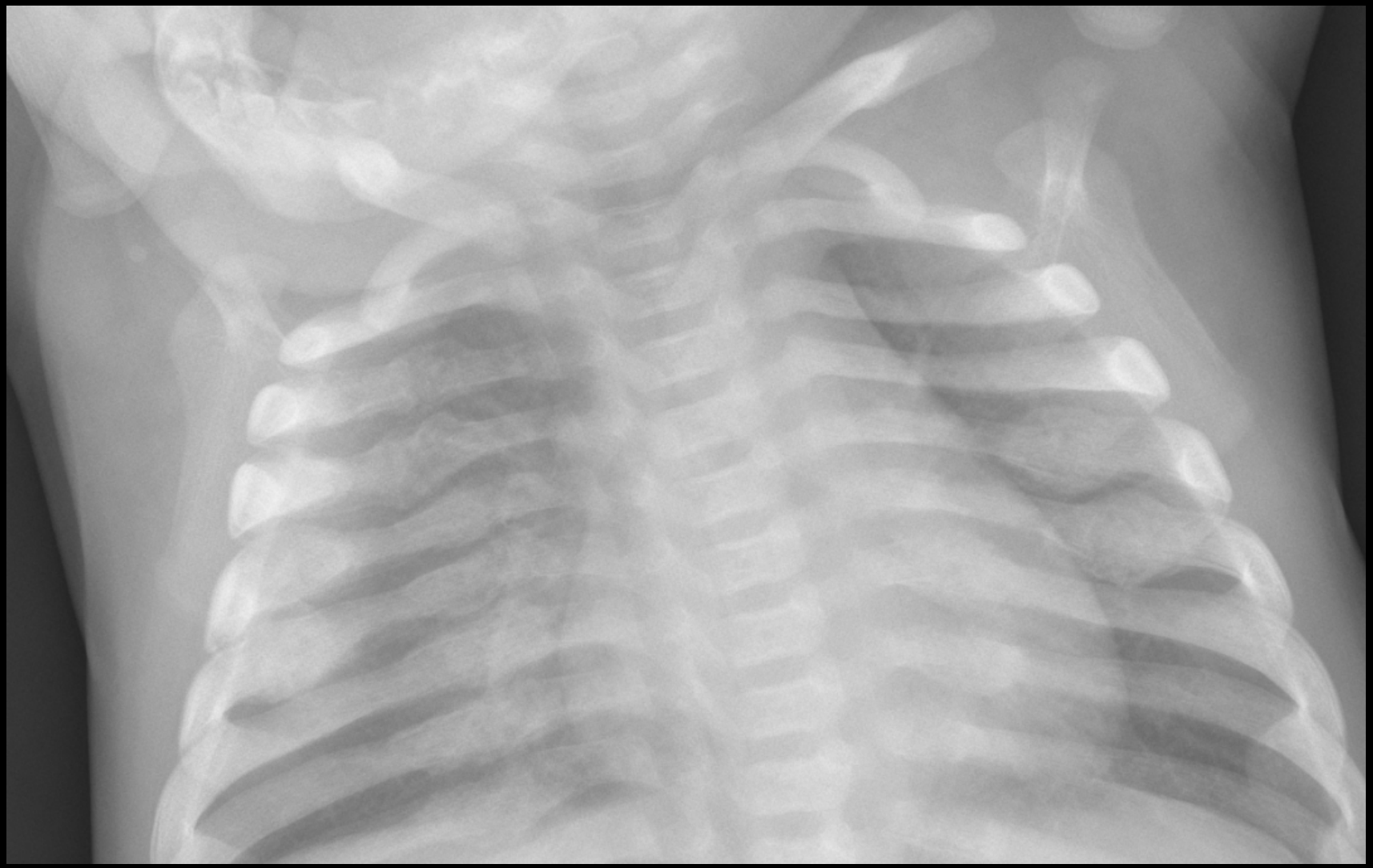

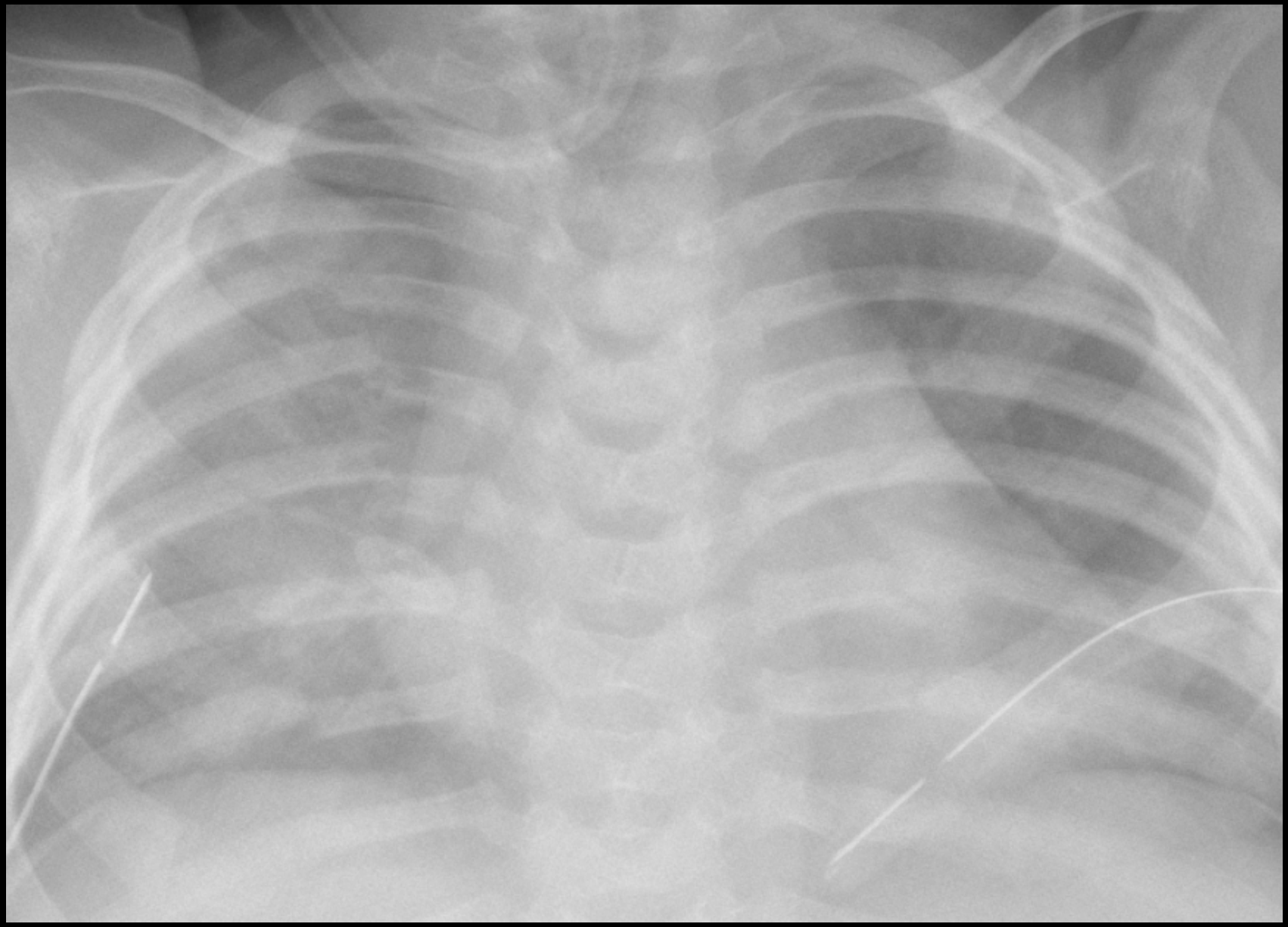

Metaphyseal Fractures

- Bucket handle or corner fractures
- Virtually pathognomonic of abuse
- Result of violent shaking or stretching of limb
- Most common locations
  - Femur
  - Tibia
  - Humerus

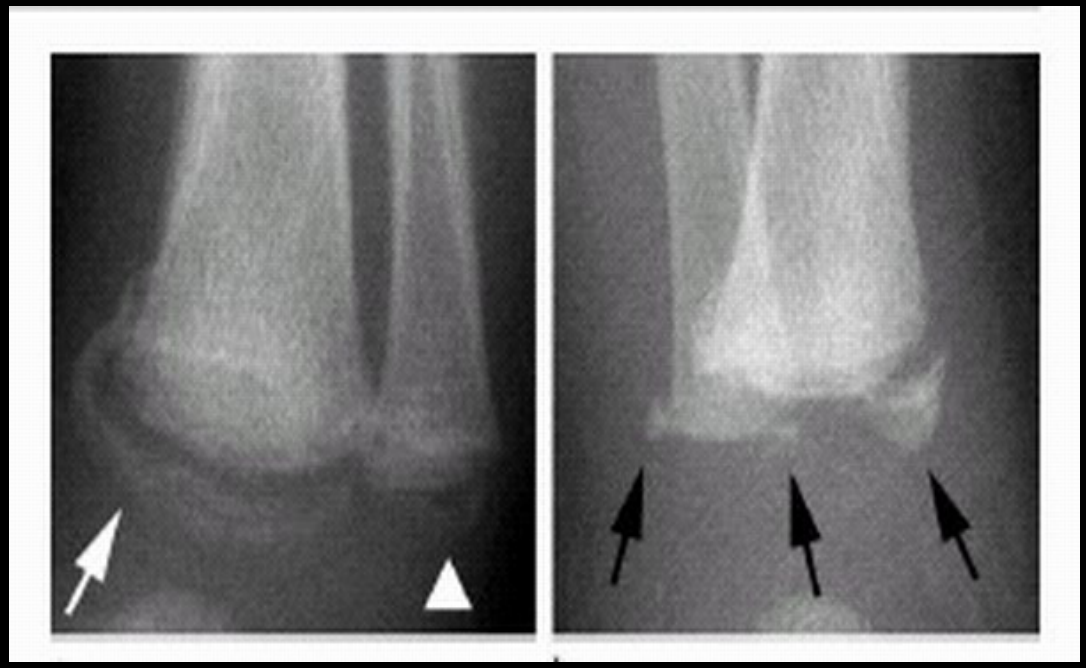

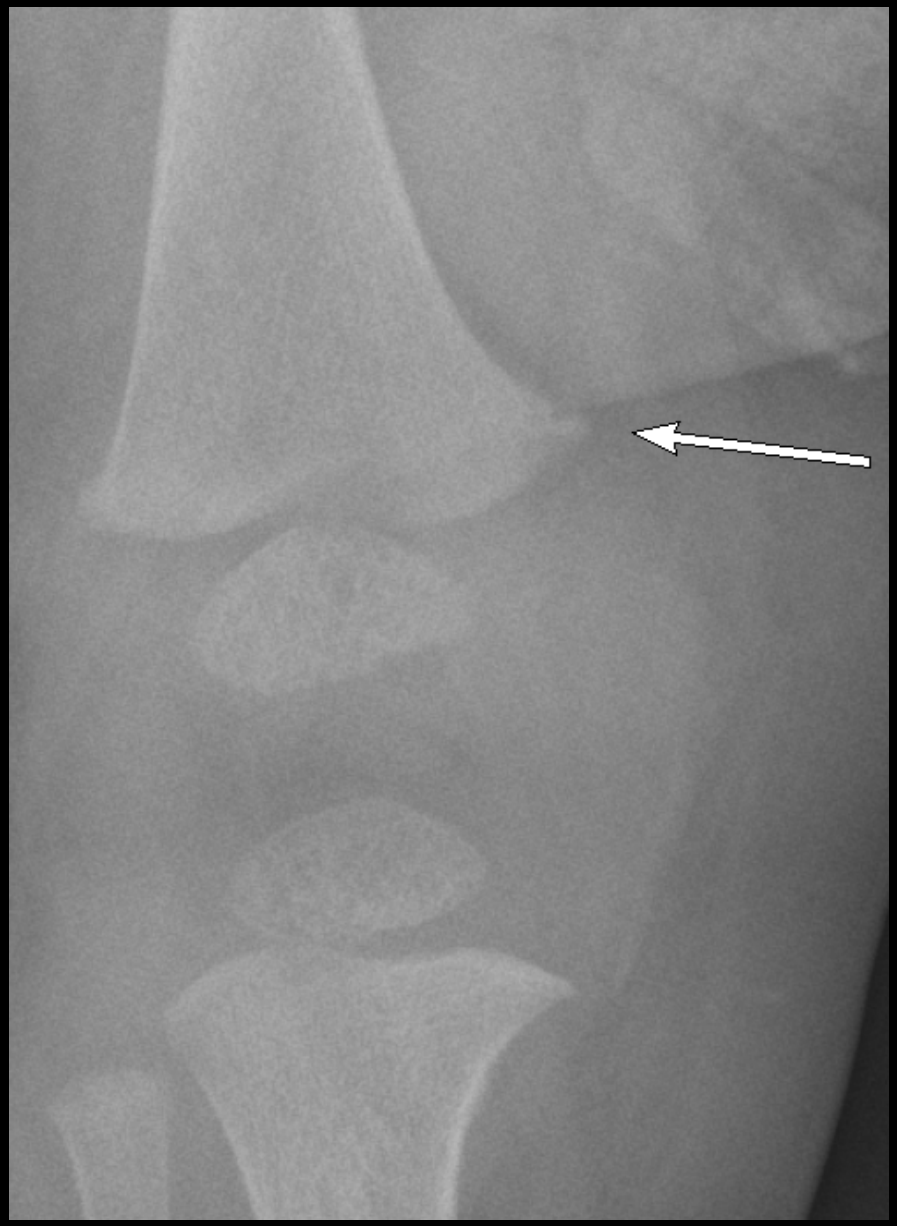

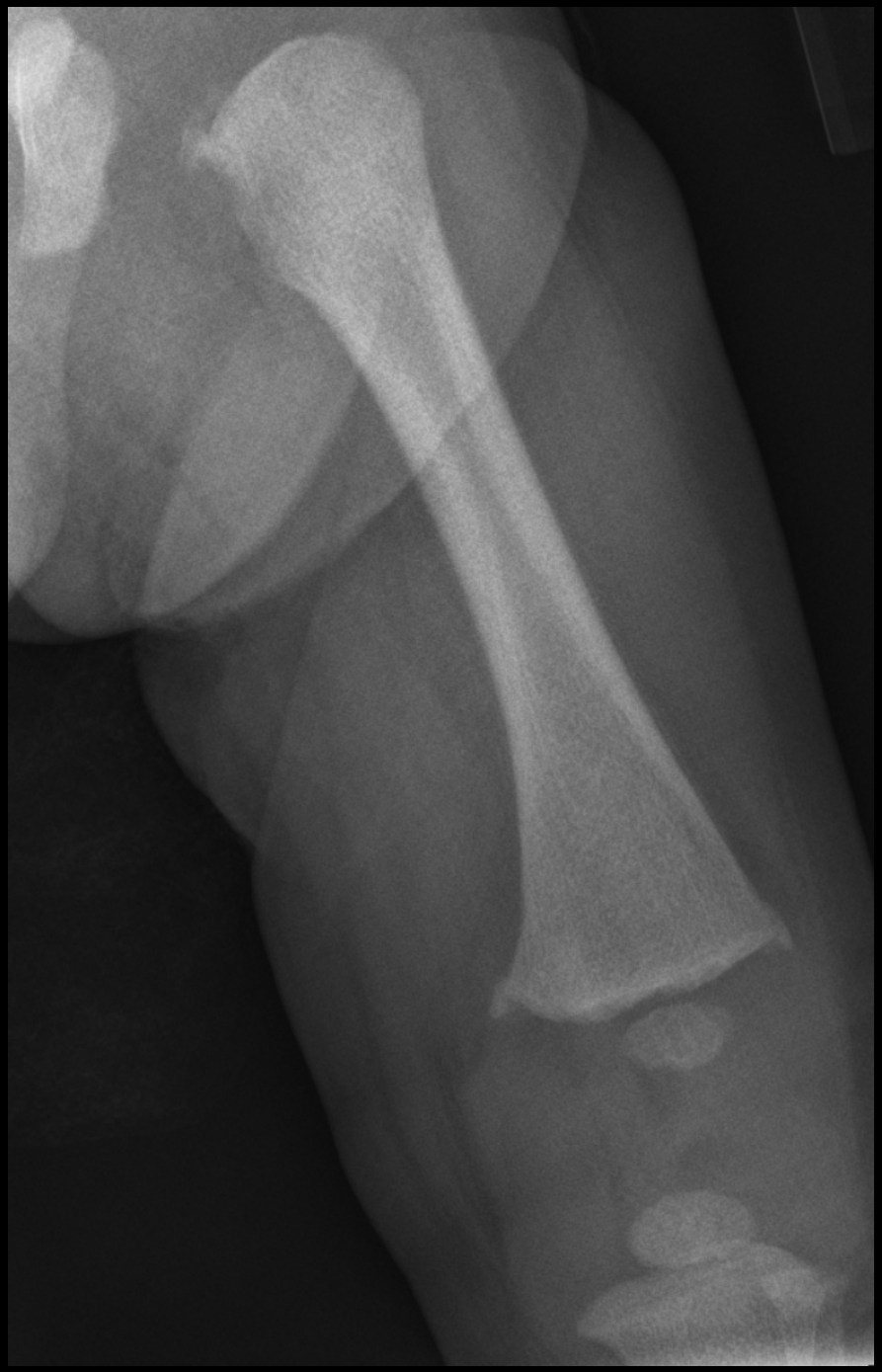

Metaphyseal fractures of the proximal and distal left femur are identified in a 3 month old presenting with bruises to the face, chest, and left side. Mother states that the father fell while holding the patient.

Multiple rib fractures and long bone fractures were revealed on skeletal survey. Patient discharged to maternal grandparents.

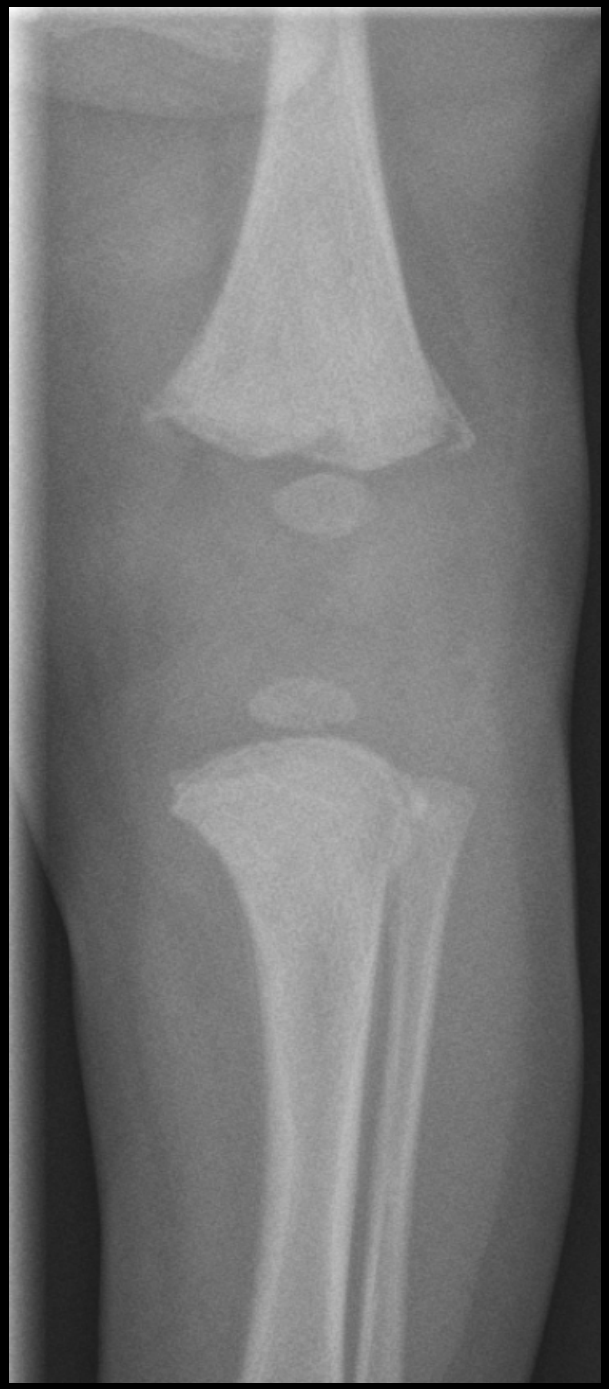

This 4 week old infant presented with scalp swelling. A head CT revealed a parietal fracture and a subarachnoid hemorrhage.

A skeletal survey showed multiple rib fractures and metaphyseal corner fractures of the distal left femur and a bucket fracture of the proximal left tibia.

Scapular Fractures

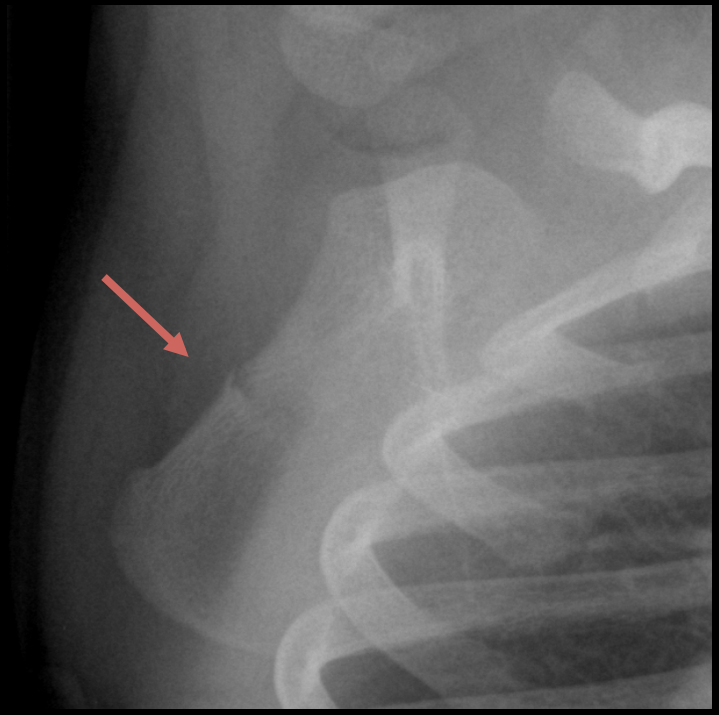

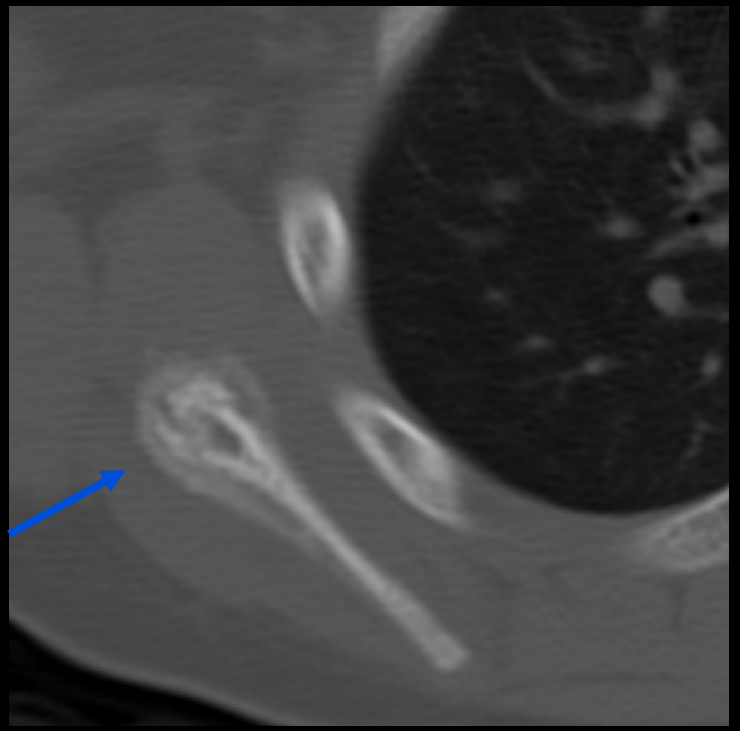

The acute (red arrow) and healing (blue arrow) appearances of a right scapular fracture are demonstrated in a 2 year old with multiple long bone fractures and bruises. Scapular fractures require a significant amount of force and are highly suspicious for abuse.

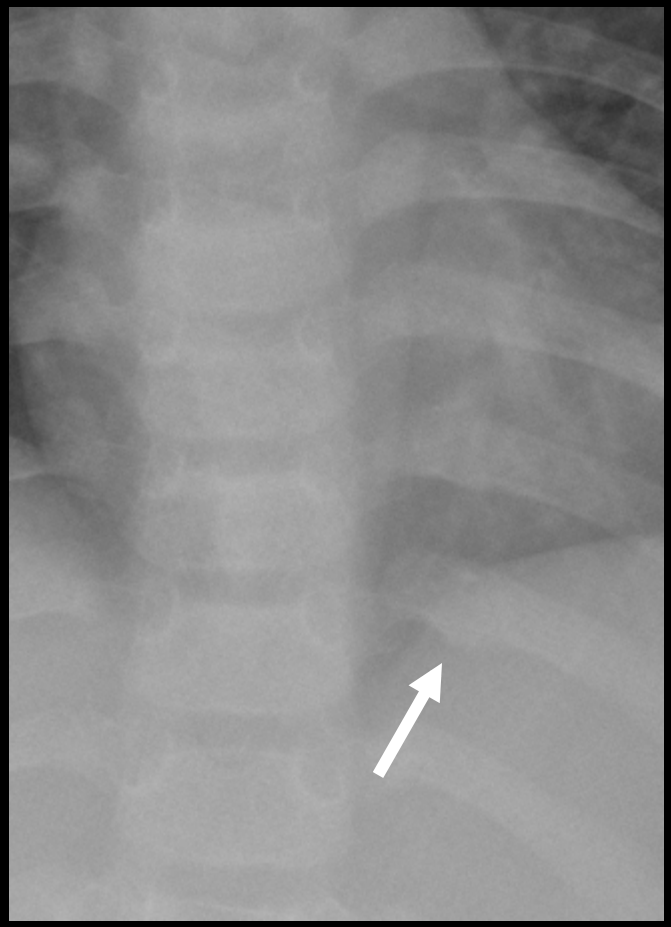

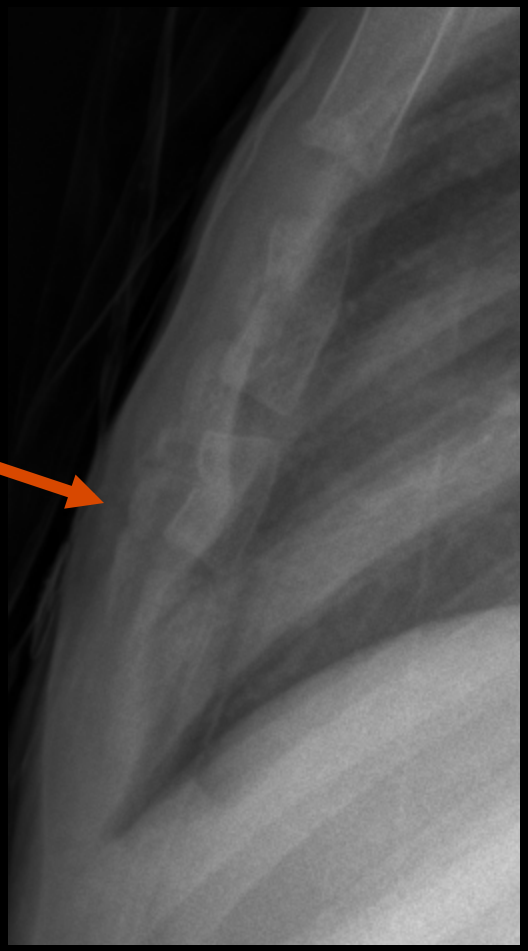

Posterior rib and a complex sternal fracture in a 5 year old child who presented with pain after falling over in the bathtub. This patient also had mesenteric and scrotal tears.

Bruising

Inflicted Bruising Locations

Regions of the body (shaded area) where bruises were significantly more likely to occur in a child with confirmed physical abuse than in one where physical abuse was excluded.

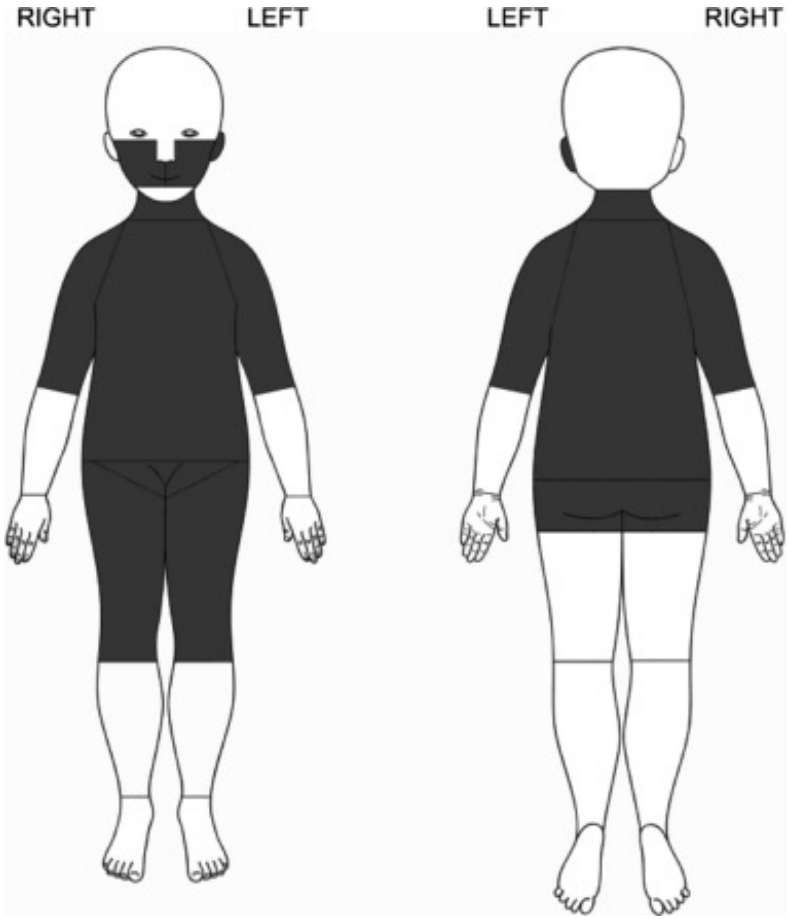

Kemp A M et al. Arch Dis Child doi:10.1136/archdischild-2013-304339

Copyright © BMJ Publishing Group Ltd & Royal College of Paediatrics and Child Health. All rights reserved.

ADC

Accidental Bruising Locations

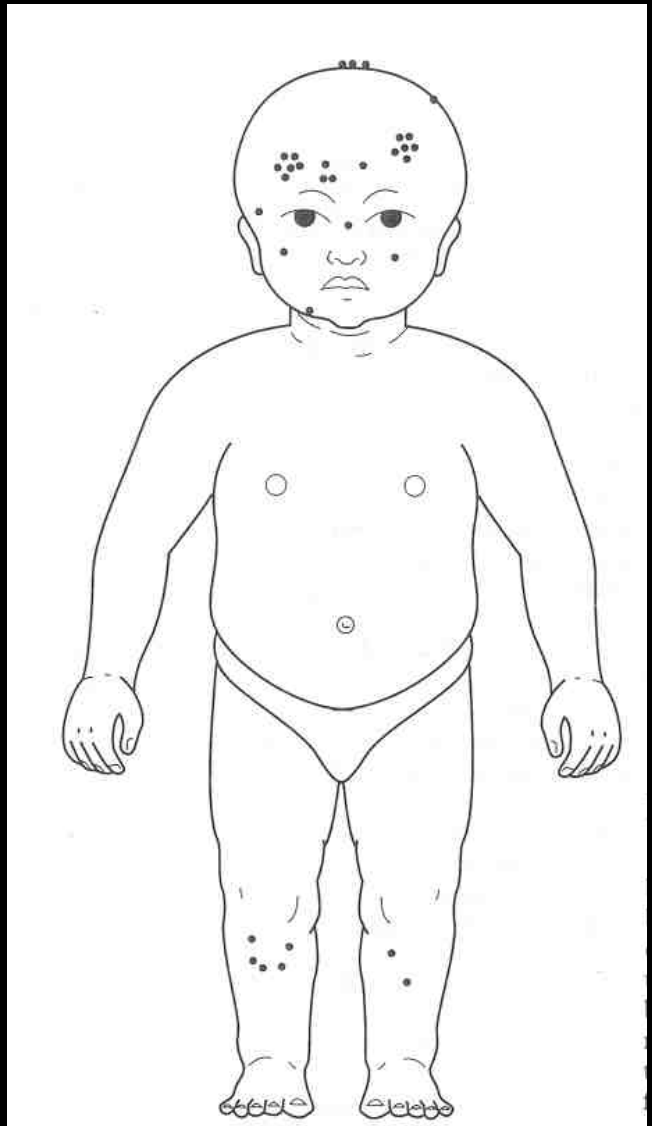

Figure 1 Illustration of the approximate sites of all the observed bruises.

Bruising

Bruising on the pinna is especially concerning for non-accidental trauma

Other Concerning Injuries

Subconjunctival Hemorrhages

Frenulum Tear

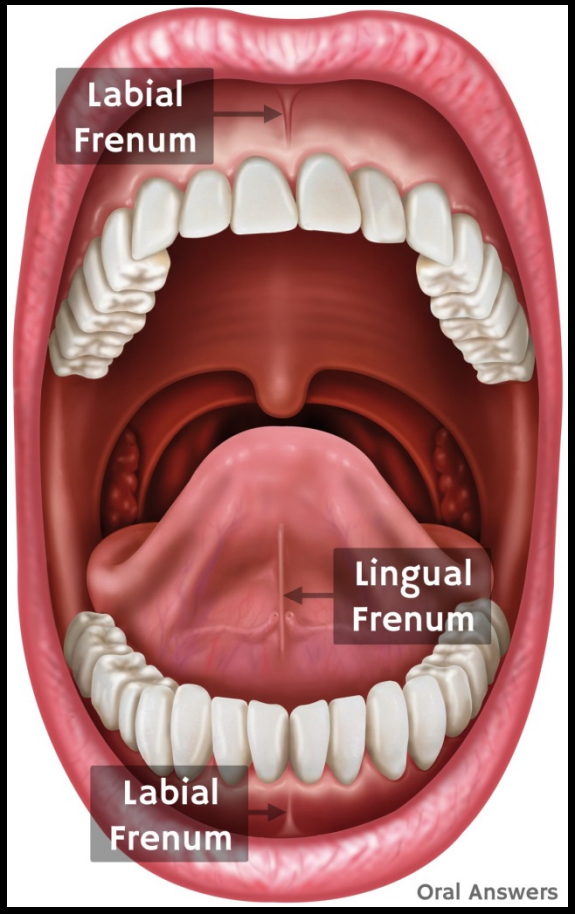

Retinal Hemorrhages

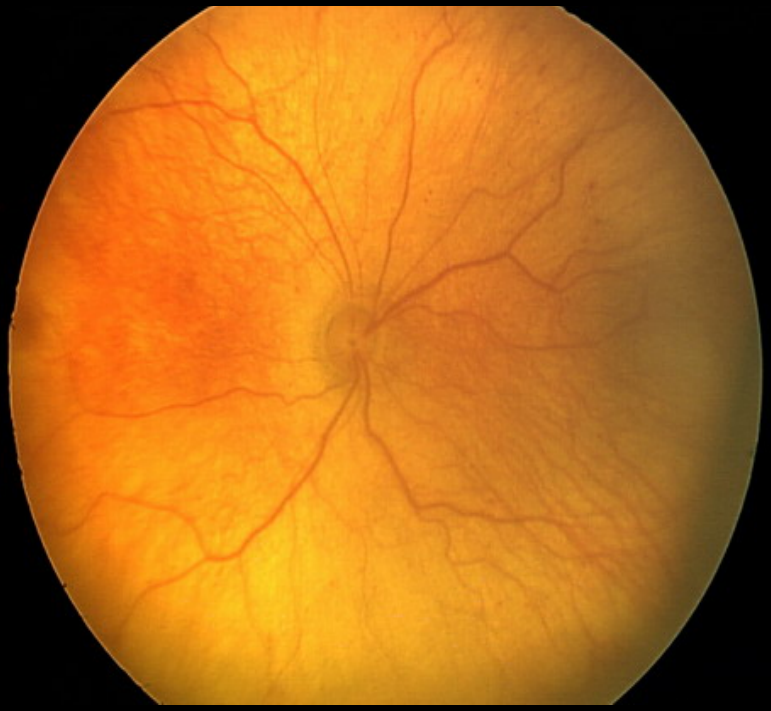

Case 1

Case 1

- 2 month old ex 35 week premature infant
- Several day history of respiratory distress
  - Nasal congestion
  - Wheezing
- Presented to OSH after apneic episode at home
- Evaluated in trauma bay
  - Increased work of breathing
  - Coarse BS
- Admitted to PICU for bronchiolitis

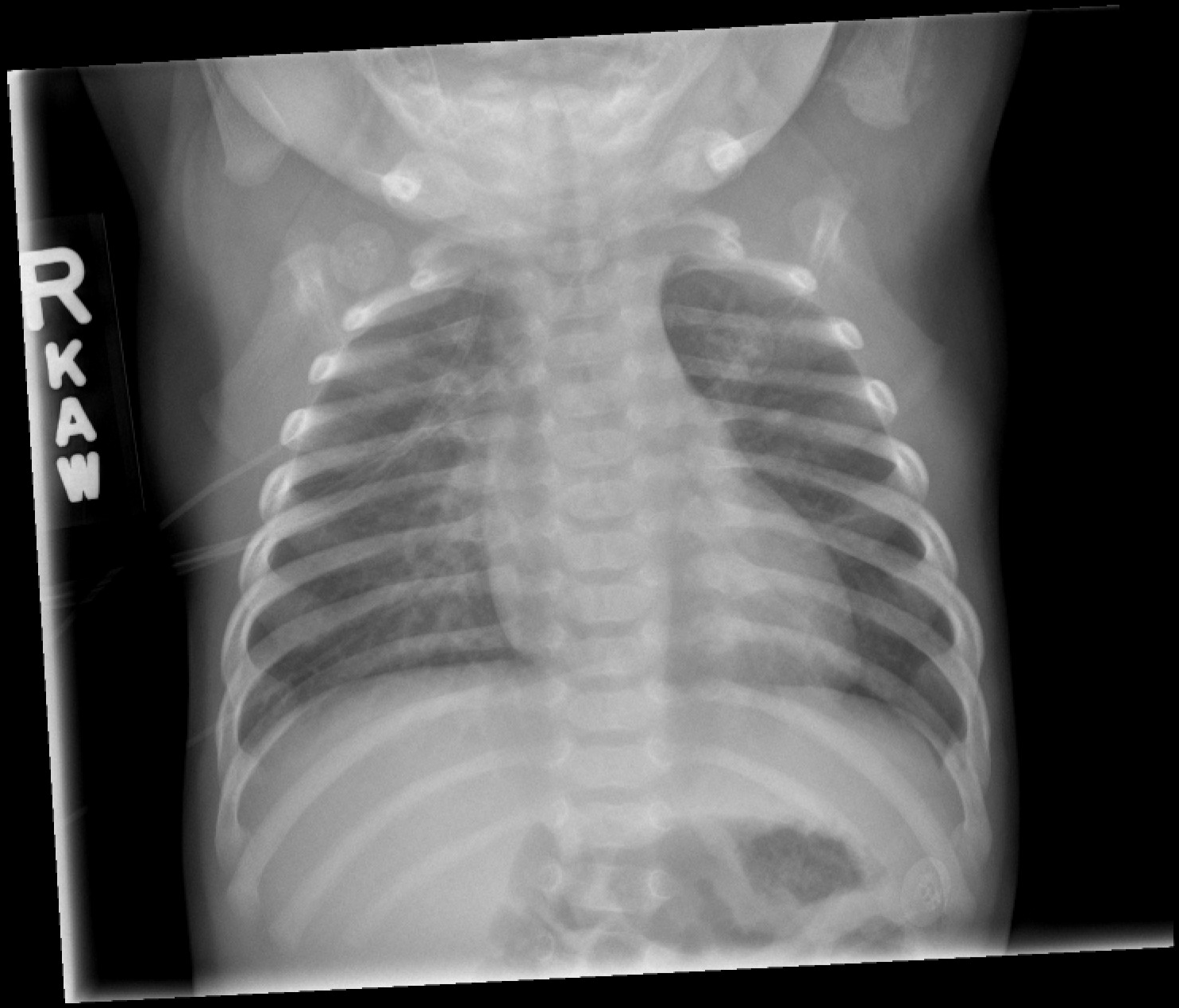
R
KAW

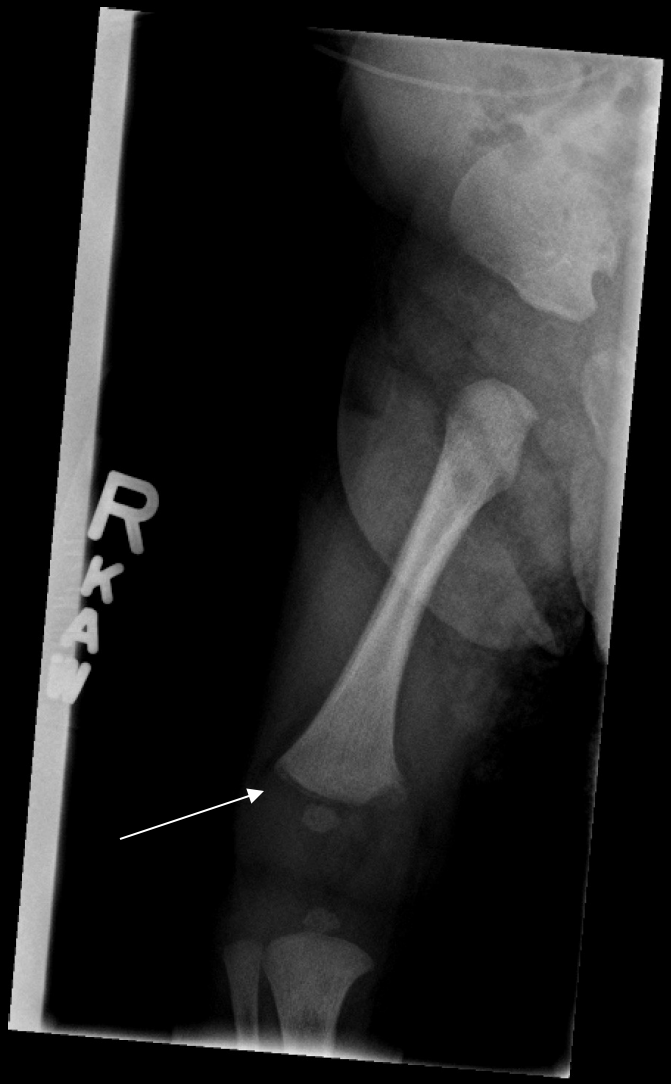
R

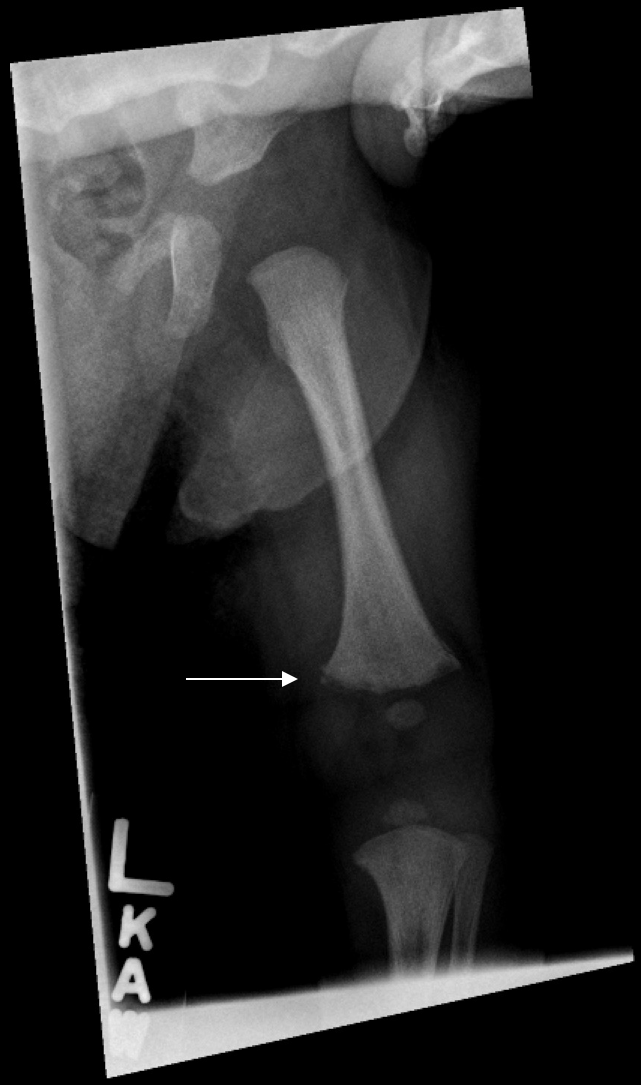
L

Total of 15 fractures

Acute and Healing

What would you expect on his physical exam?

Case 2

Case 2

- Almost 4 month old
- 5 day hx vomiting 1-2 x/day
- NBNB emesis immediately – 2 hours after feeding
- Sleeping more
- Increased fussiness but consolable
- Decreased PO
- No fever
- No diarrhea

Case 2

- Exam
  - Fussy, high pitched cry during exam and when lying supine
  - Consoled when held by mother and sleeps
  - Anterior fontanelle slightly full but soft
  - Lungs clear
  - Abd soft
  - Normal tone
  - Well perfused
  - No bruising

Based on the exam description,

Is this an ill appearing child?

Differential diagnosis?

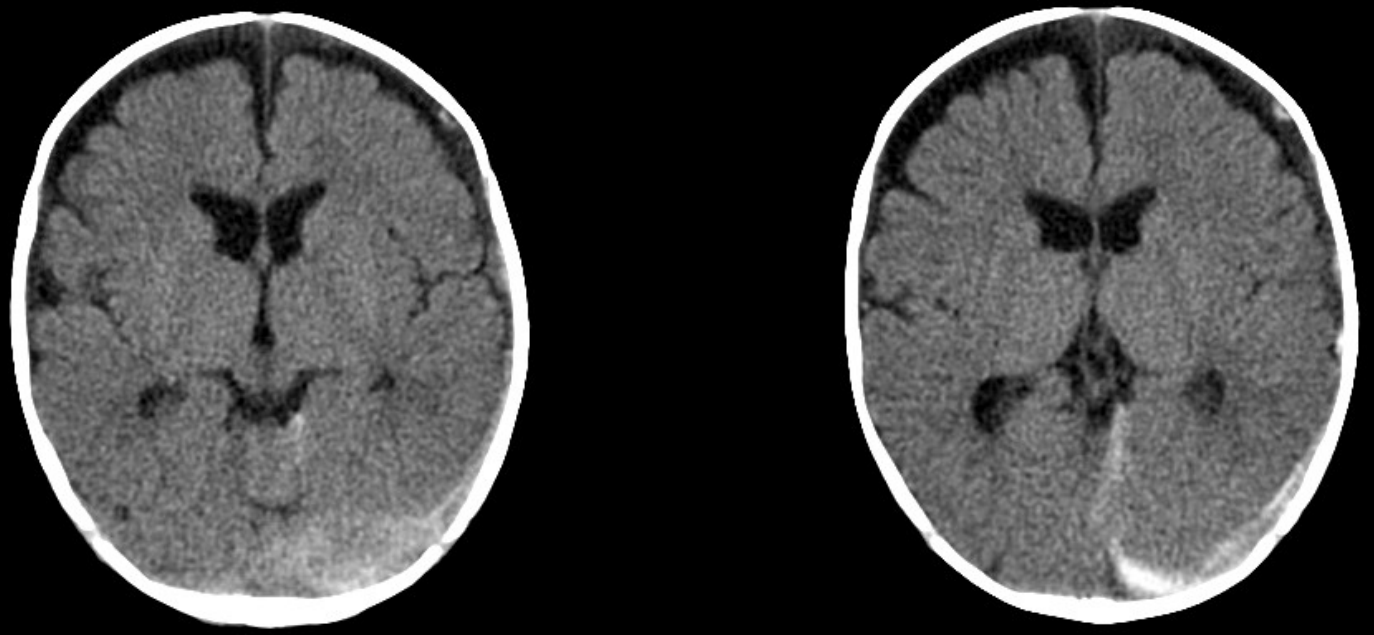

Subdural hemorrhage

Ophthalmology evaluation revealed retinal hemorrhages

Retinal Hemorrhages

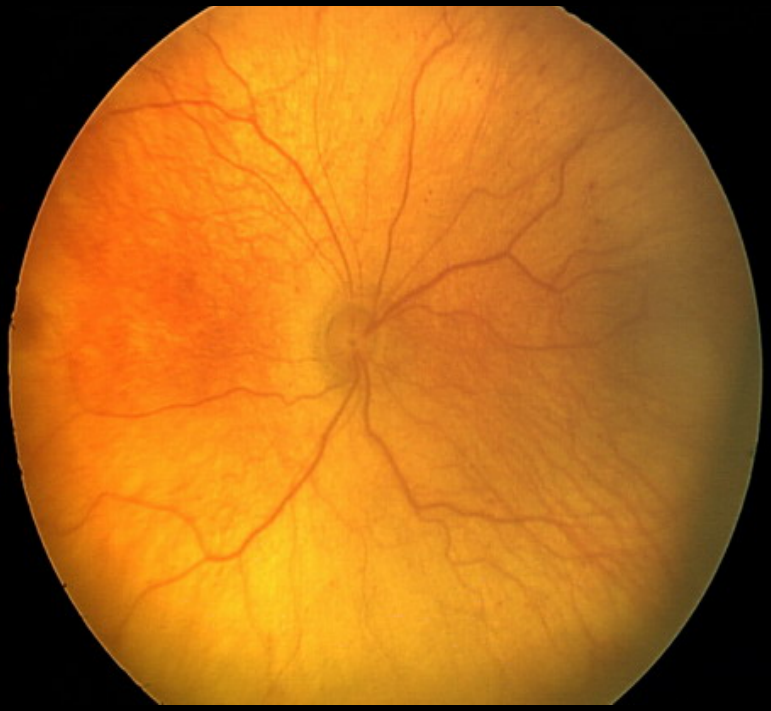

Case 3

- 3 month old with history of congestion
- Father went to pick him up out of his bouncy seat
  - Started crying
  - Continued to be fussy thereafter
- Seen by PMD for persistent fussiness
- Referred to CCHMC

Case 3

Bruising on left leg

Petechiae surrounding eyelids, most prominent on upper eyelids

Subconjunctival hemorrhages to medial aspect of sclera bilaterally

Case 3 Test Results

- Head CT
  - No intracranial injury
- Skeletal survey
  - Possible metaphyseal corner fracture proximal right tibia
- AST = 93
- Abdominal CT
  - No organ injury
  - Small pleural effusion…

Case 3

Acute fracture of posterior 9th rib

Acute fracture of posterior 10th rib

Sentinel Injuries

Sentinel Injuries in Infants Evaluated for Physical Abuse

- Case control retrospective study of 401 infants < 12 months old
- Sentinel injury
  - previous injury reported in the medical history suspicious for abuse because infant could not cruise or the explanation was implausible

Sheets LK, Leach ME, Koszewski IJ, Lessmeier AM, Nugent M, Simpson P. Sentinel injuries in infants evaluated for child physical abuse. Pediatrics. 2013

Sentinel Injuries in Infants Evaluated for Physical Abuse

- Of 200 infants who were definitely abused, 55 (27.5%) had a sentinel injury
- Types of sentinel injuries:
  - 80% bruise
    - Head (face, forehead, ear) = 62%
    - Extremity =21%
    - Trunk = 17%
  - 11% intraoral injury
  - 7% fracture

Medical providers were aware of the sentinel injury in 41.9% cases

Sheets LK, Leach ME, Koszewski IJ, Lessmeier AM, Nugent M, Simpson P. Sentinel injuries in infants evaluated for child physical abuse. Pediatrics. 2013

Case 4

- 2 month old male ex 37 week infant, no birth complications
- Mother reported that father was holding pt, pt had episode of emesis and milk coming out of his nose, father “freaked out and was running up the stairs in flip flops and fell forward”
- Per mother, father says he does not think he fell onto the pt, not sure how pt landed
- No LOC
- Subsequently ate a full bottle, no emesis
- Acting normally

Case 4

- Evaluated in Trauma Bay
- HR 144-162
- RR 39-53
- Well appearing
- Moving all extremities
- Normal
  - Heart
  - Lungs
  - Abdomen

Case 4

- Social history
  - Lives with mother and father and siblings
    - 6 and 4 year old different father
    - Pt and 2 year old sibling current father
  - Father released from jail in September after 4 month stay
  - Father cares for children during the day while mother is at school
  - Mother denies drug / alcohol use and domestic violence

Case 4

- Head CT
  - No traumatic intracranial abnormality or skull fracture
  - Non-displaced fracture through posterior aspect of left 1st rib
- Skeletal Survey
  - Left 1st posterior rib fracture with signs of healing

Case 4

- Presented to Urgent Care 11 days previously
- CC = red bump on tongue
- Erythema to tip and side of tongue, distal 3rd
- Posterior pharynx mildly erythematous
- Otherwise well appearing
- Eating well
- Rec follow-up with PMD the next day

Sentinel Injuries in Infants Evaluated for Physical Abuse

- Of 200 infants who were definitely abused, 55 (27.5%) had a sentinel injury
- Types of sentinel injuries:
  - 80% bruise
    - Head (face, forehead, ear) = 62%
    - Extremity =21%
    - Trunk = 17%
  - 11% intraoral injury
  - 7% fracture

Sheets LK, Leach ME, Koszewski IJ, Lessmeier AM, Nugent M, Simpson P. Sentinel injuries in infants evaluated for child physical abuse. Pediatrics. 2013

Case 5

- 2 month old brought to the ED by mother because of bruising to forehead and redness to eyes
- Was in care of father the day prior
  - reportedly fell from a swing
  - eyes became red after crying

Case 5

- Exam:
- Calm, alert, interactive, follows faces
- Cardiac and lung exam normal
- Abd soft and non-tender
- Extremities normal without rash or bruising
- Minimal supraorbital swelling of right eye
- Moderate subconjunctival hemorrhages bilaterally

Case 5

- Skeletal survey = Normal
- Head CT = Normal
- ED plan: “2 month old with subconjunctival hemorrhages and small facial contusion, otherwise well appearing. Mom does not have concern about intentional injury. Head CT/SS reassuring. Fed here and is smiling and interactive.”
- Discharged home to f/u with ophtho for formal eye exam
- PMD aware

Case 5

- Presented to ED 3 days later
- In care of father while mother at work
  - Father was reportedly “tired” that day
- When mother returned home BM was noted to be pale / grey, swelling to left head, blank stare, no responsive smile, increased subconjunctival hemorrhages
- Mother brought to ED via private car

Case 5

- Intubated due to lack of responsiveness
- CT:
  - Displaced fracture of left parietal bone
  - Bilateral supra-tentorial extra-axial hemorrhage
  - Generalized global swelling and loss of grey-white matter differentiation compatible with a global hypoxic event
- Admitted to PICU
- Ophtho exam:
  - too numerous to count retinal hemorrhages bilaterally

ART

Case 5

- Grandmother expressed concern about patients father “verbally abusive and very controlling”
- Mother went back to work after maternity leave 3 days prior to first ED visit
- Prior admission for FTT
- Open CPS case for maternal marijuana use during pregnancy

Case 5

- Father confessed to shaking patient and throwing him against the wall
- Father arrested
- Mother withdrew life support

The End

References

- Sheets LK, Leach ME et al. Sentinel injuries in infants evaluated for child physical abuse. Pediatrics. 2013;131 (4):701-707
- Jenny C, Hymel KP et al. Analysis of missed cases of abusive head trauma. JAMA. 1999;281 (7):621-626.
- Kunen S, et al. Under diagnosis of child abuse in emergency departments. Acad Emerg Med 2003; 10 (5):546a
- Pierce et al. Bruising characteristics discriminating physical child abuse from accidental trauma. Pediatrics 2010;125:67
- Christian C et al. The evaluation of suspected physical abuse. AAP Committee on Child Abuse and Neglect.
- Pless IB et al. A reappraisal of the frequency of child abuse seen in pediatric emergency rooms. Child Abuse Negl 1987.
- Higginbotham et al. Utility of a child abuse screening guideline in an urban pediatric emergency department. J trauma Acute Care surg 2014