Pediatric Upper Airway Disease

Rick Strait, MD
Division of Emergency Medicine
Cincinnati Children's Hospital

Airway anatomy

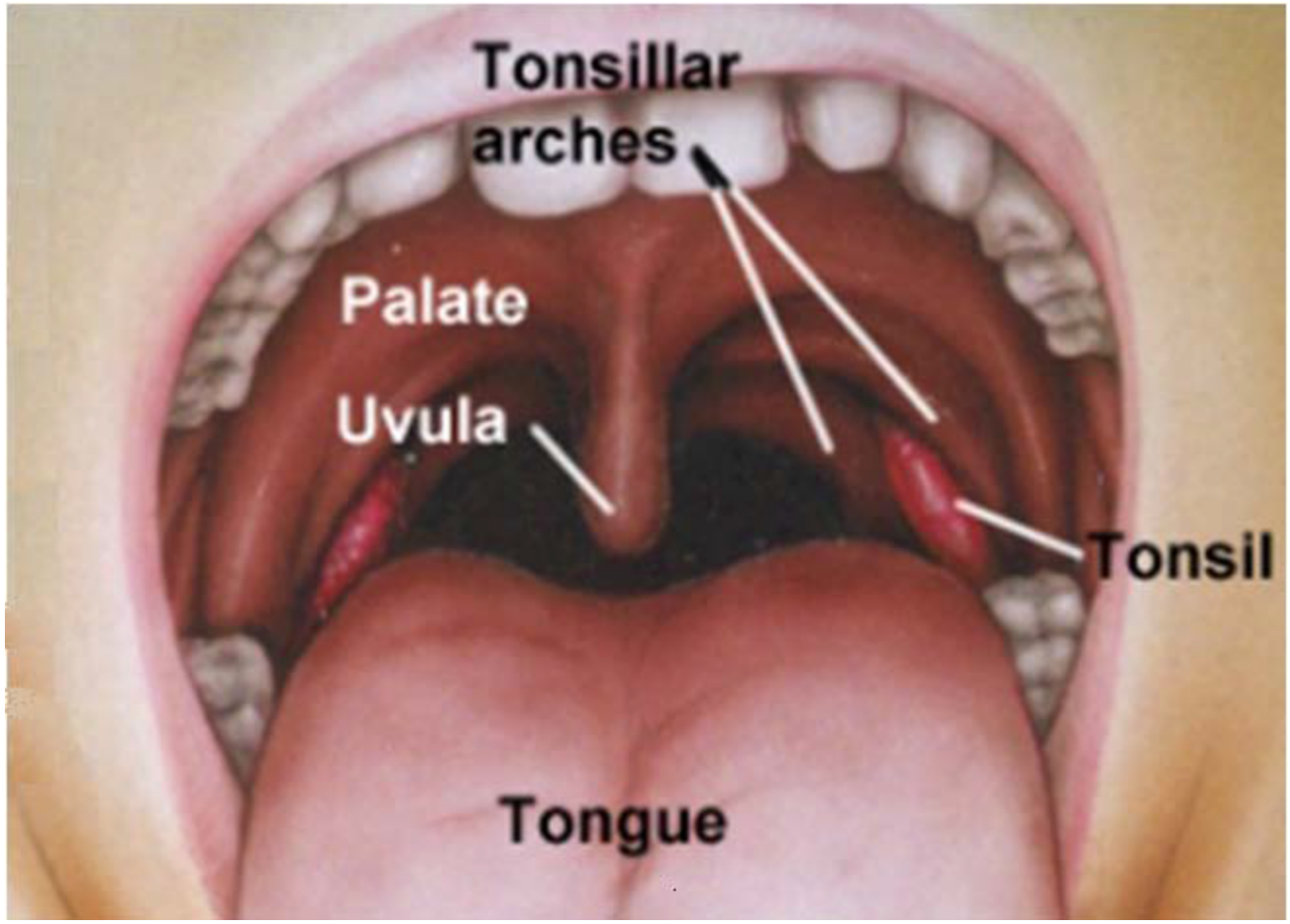

Airway anatomy

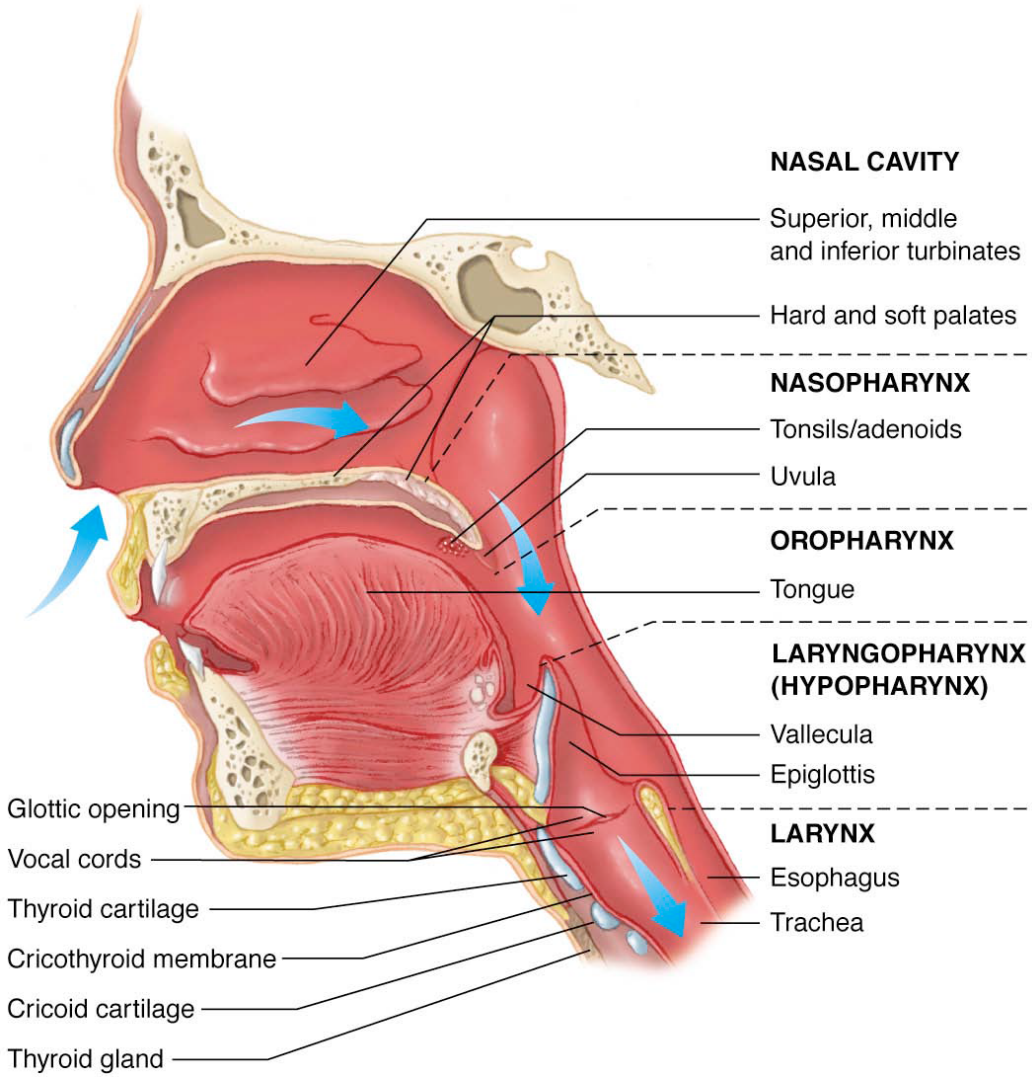

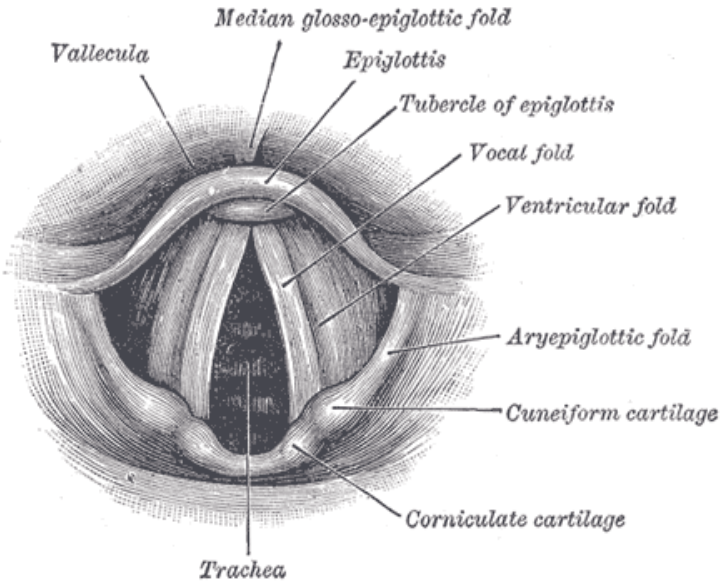

Airway anatomy……. from an intubator's point of view

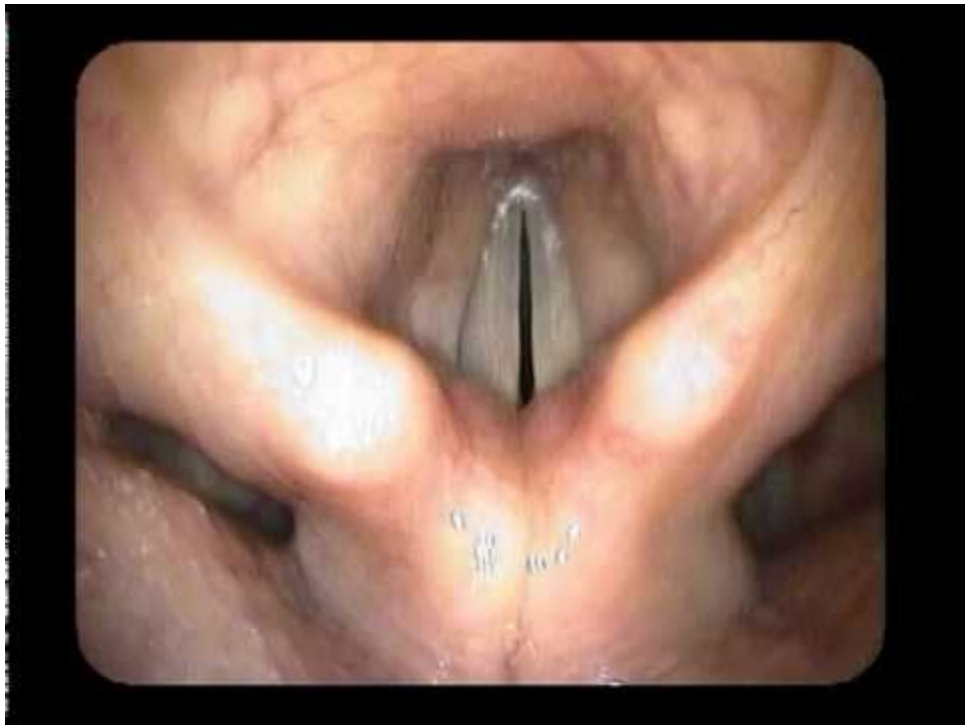

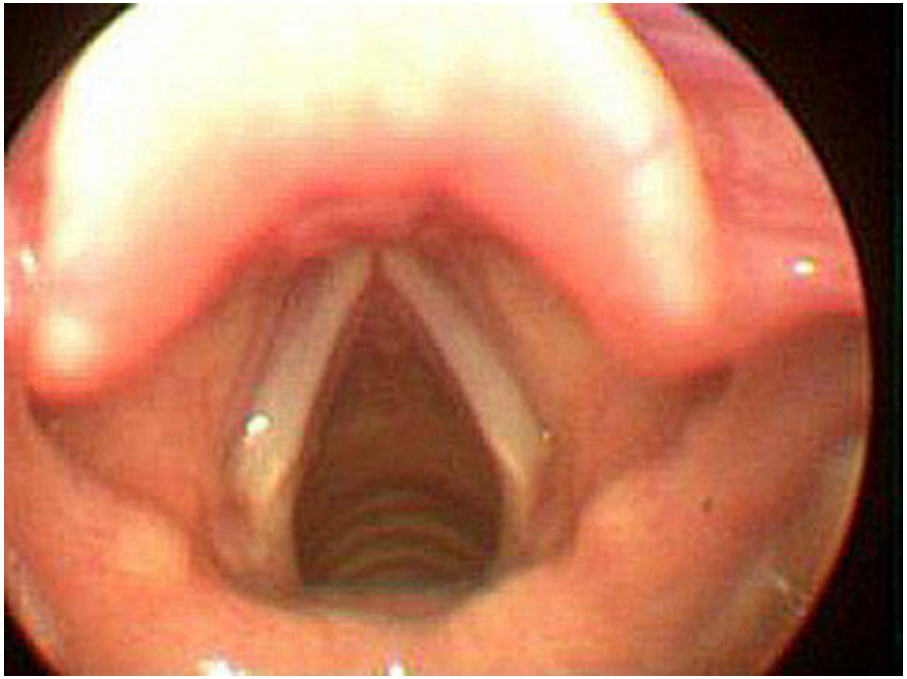

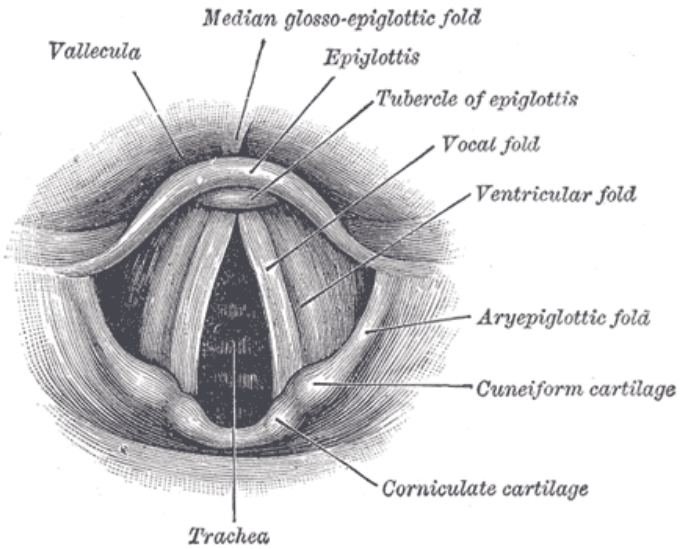

Airway anatomy……. from an intubator's point of view

How is the pediatric airway different from that of an adult?

- Obligate Nasal Breathers
- Large Tongue
- Large Occiput
- Larynx and Trachea are funnel shaped
- Vocal Cords slant anteriorly
- Larynx located higher in neck (at C4 vs. C6 in adults)
- Narrowest part of the pediatric airway is at cricoid cartilage (until age 5). In adults the narrowest part is at the glottis opening
- Glottis Location Different:
  - Premature Babies at C3
  - Newborns C3-C4
  - Adults C5

*tracheal rings are more flexible in infant than adult

How is the pediatric upper airway different from that of an adult?

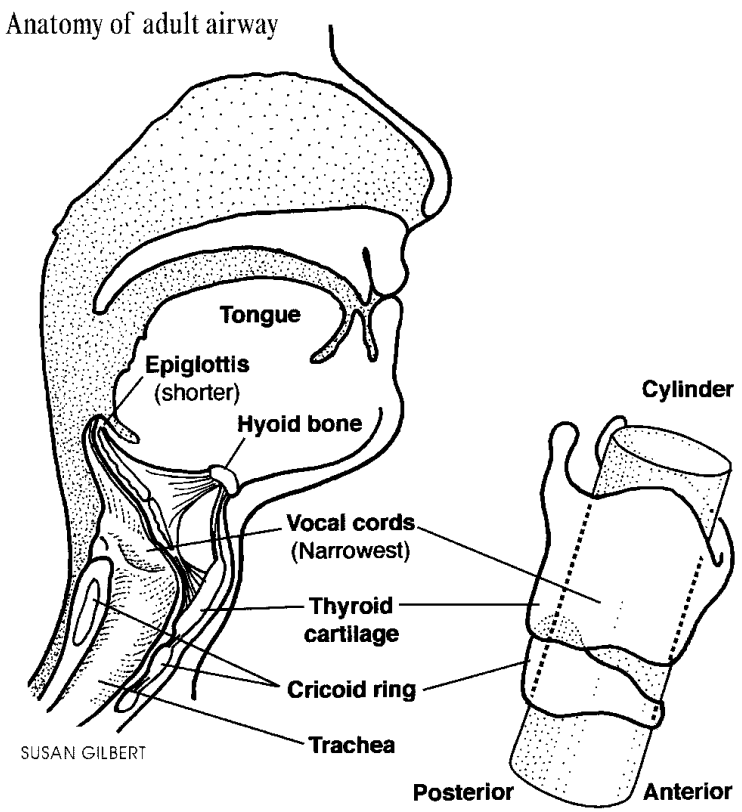

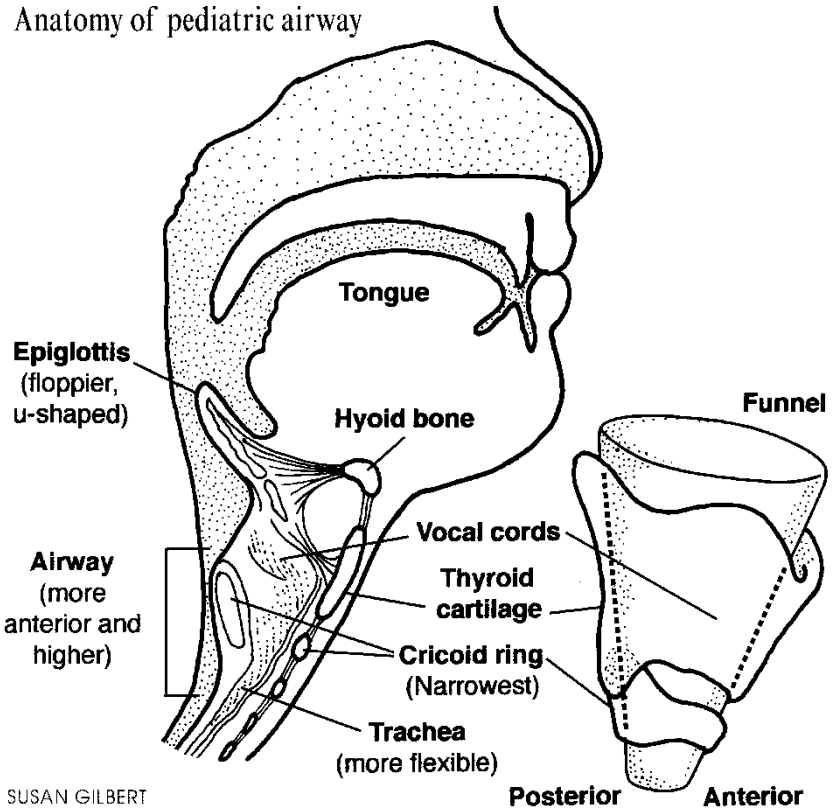

How is the pediatric airway different from that of an adult?

Effect of the occiput on the airway

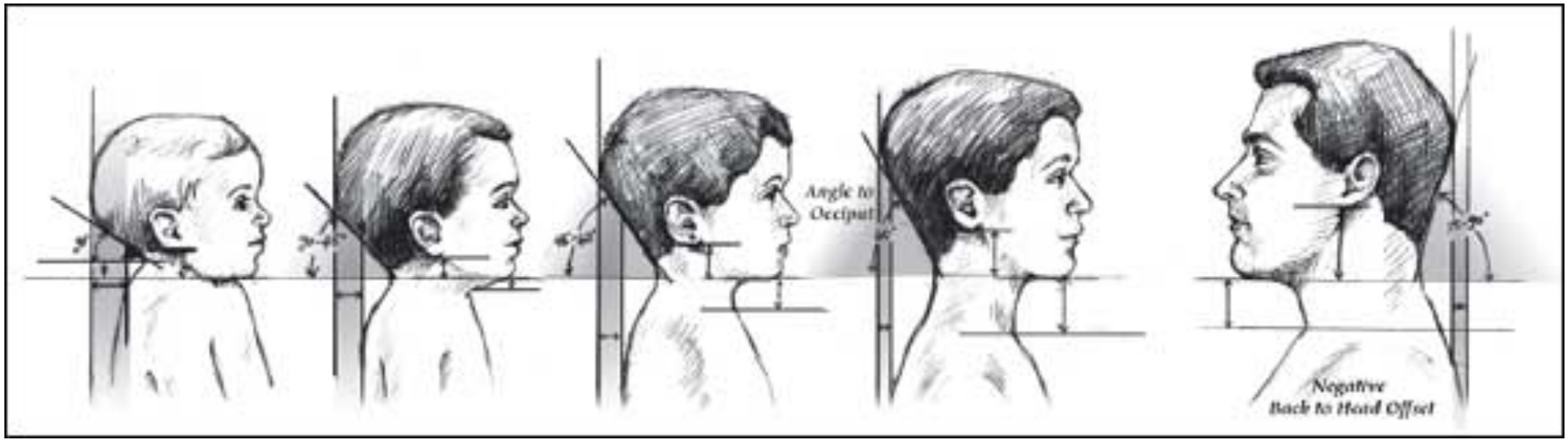

How is the pediatric airway different from that of an adult?

Glottis Location Differs

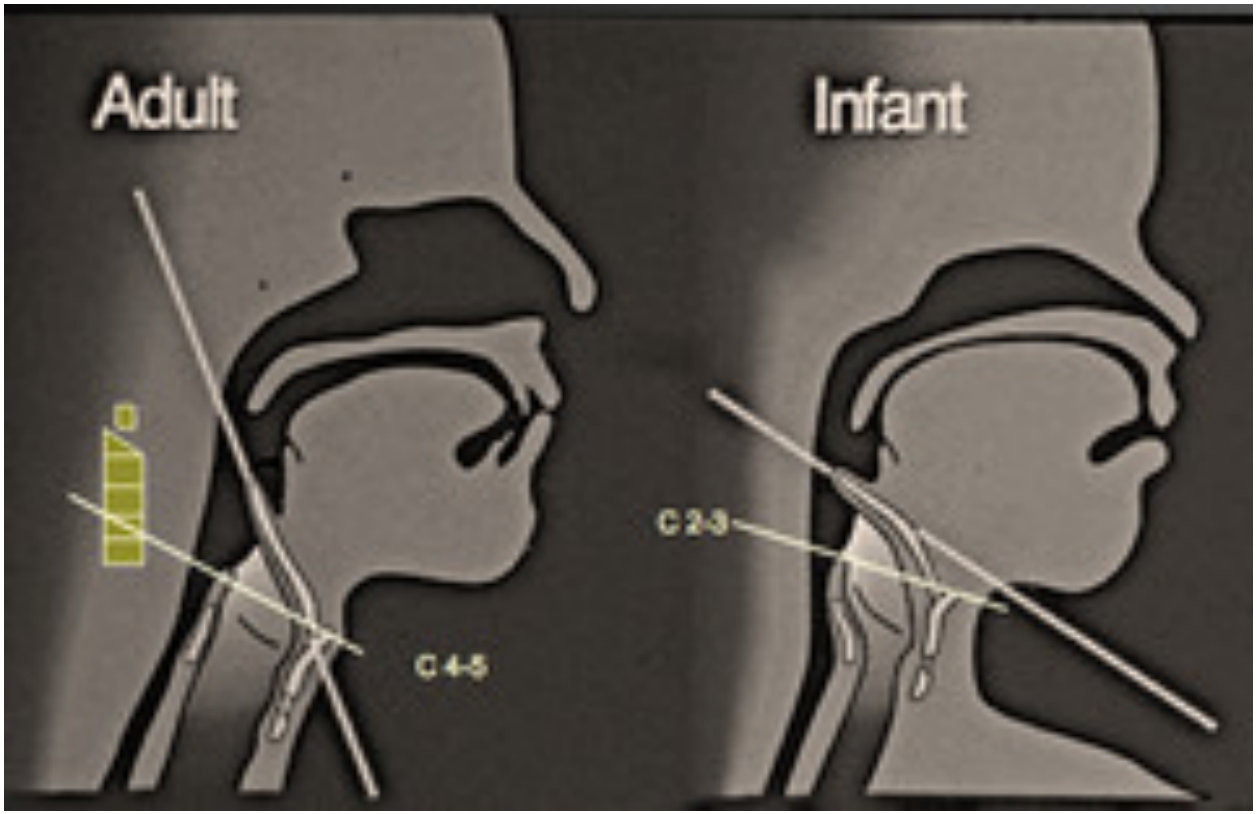

Case 1

- 12 mo with runny nose for 1 day and today with barky cough and fever to 102.

https://youtu.be/Qbn1Zw5CTbA

https://youtu.be/5-LIqdjqHts

Croup – how does it present?

- Croup usually begins with nonspecific respiratory symptoms (ie, rhinorrhea, sore throat, cough).
- Typically occurs in children between 6 months and 6 years of age
- Fever is generally low grade (38-39°C) but can exceed 40°C.
- Within 1-2 days, the characteristic signs of hoarseness, barking cough, and inspiratory stridor develop, often suddenly, along with a variable degree of respiratory distress.
- Symptoms are perceived as worsening at night, with most ED visits occurring between 10 pm and 4 am.
- Symptoms typically resolve within 3-7 days but can last as long as 2 weeks.

Croup – PE findings

- The physical presentation of croup has wide variation.
- Most children have no more than a "croupy" cough and hoarse cry. Some may have stridor only upon activity or agitation, whereas others have audible stridor at rest and clinical evidence of respiratory distress.
- Some children will also have sternal retractions
- Paradoxically, a severely affected child may have "quiet" stridor secondary to a greater degree of airway obstruction. The child with croup typically does not appear toxic.
- In mild cases, respiratory sounds at rest are normal; however, mild expiratory wheezing may be heard.
- Children with more severe cases have inspiratory and expiratory stridor at rest with visible suprasternal, intercostal, and subcostal retractions. Air entry may be poor. Lethargy and agitation are due to marked respiratory difficulty and, hence, hypoxemia and increasing hypercarbia. Respiratory arrest may occur suddenly during an episode of severe coughing

Croup – what else could it be?

- Spasmodic croup (recurrent croup)
- Retropharyngeal abscess
- Subglottic stenosis
- Angioedema
- Allergic reaction
- Tracheomalacia
- Laryngeal web
- Laryngeal papillomatosis
- Laryngeal hemangioma
- Subglottic hemangioma
- Vocal cord paralysis
- Uvulitis
- Innominate artery compression
- Right aortic arch vascular ring
- Double aortic arch
- Aberrant subclavian artery
- Pulmonary artery sling
- Gastroesophageal reflux (diagnostic consideration for recurrent croup)
- Airway Foreign Body
- Esophageal Foreign Body
- Bacterial Tracheitis
- Diphtheria
- Epiglottitis
- Inhalation Injury
- Laryngeal Fractures
- Laryngomalacia
- Measles
- Mononucleosis and Epstein-Barr Virus Infection
- Peritonsillar Abscess
- Rarer etiologies in the pediatric population - Laryngeal tuberculosis, neoplasm (compressing trachea), sarcoidosis, Wegener granulomatosis



Croup – what work-up is needed?

- Croup is primarily a **clinical diagnosis**.
- Laboratory test results rarely contribute to confirming this diagnosis.
- Pulse oximetry readings are within the normal reference range for most patients
- Standardly, arterial blood gas (ABG) measurements are unnecessary
- Laryngoscopy is indicated only in unusual circumstances such as, the course of illness is not typical, the child has symptoms that suggest an underlying anatomic or congenital disorder.
- Plain films can verify a presumptive diagnosis or exclude other disorders causing stridor and hence mimic croup.
  - A lateral neck radiograph can help detect other diagnoses such as an aspirated foreign body, esophageal foreign body, congenital subglottic stenosis, epiglottitis, retropharyngeal abscess or bacterial tracheitis (thickened trachea). Radiographs can be used as a tool to help confirm this diagnosis, but they are not required in uncomplicated cases.

Croup – what are the radiograph findings?

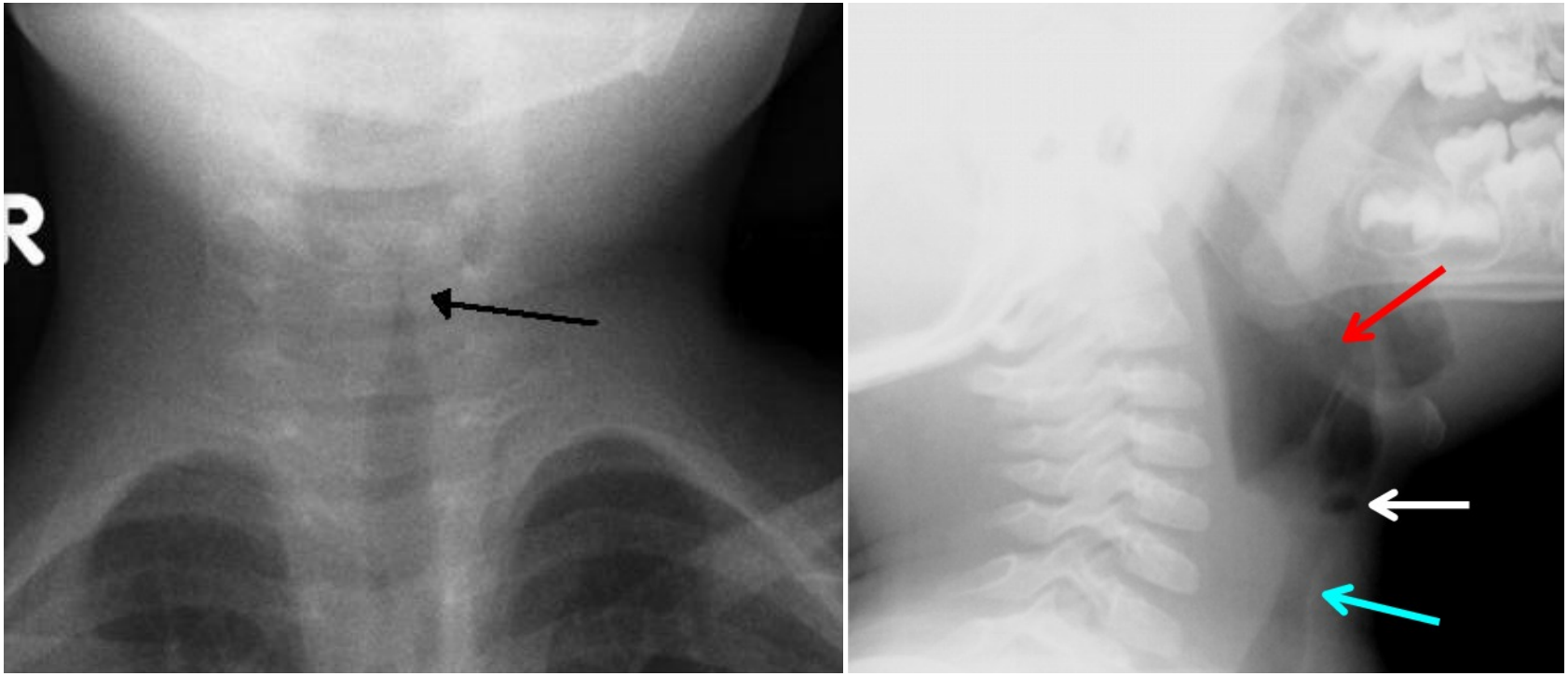

The anteroposterior (AP) radiograph of the soft tissues of the neck classically reveals a steeple sign (also known as a pencil-point sign), which signifies subglottic narrowing, whereas the lateral neck view may reveal a distended hypopharynx (ballooning) during inspiration.

Croup – what treatment is needed?

- IVF
- Racemic epinephrine
- Cool mist
- Steroids
- Intubation
- Hospitalization
- Discharge instructions

Cincinnati Children's Hospital Medical Center
513-636-4293
Take-Home Instructions for the Patient
Croup

Description and Causes: Croup is an infection of the upper airway and voice box, caused by a virus. Croup is common between the ages of 6 months and 4 years. Croup usually starts with a slight fever and runny nose. This is followed by a hoarse voice, barky cough, noisy breathing, and shortness of breath. Croup will often get worse at night.

Treatment and Home Care: Most children with croup do not need antibiotics or hospital care. They usually get better in 5-6 days with care at home to keep them comfortable. Sometimes cortisone medicine is used. You should:

- **Have your child drink a lot of warm fluids (water, sodas, juices).**
- **Comfort your child to decrease crying and irritability.**
- **Use a cool-mist vaporizer in the room where they sleep.**
- **Elevate your child's head on pillows to ease the breathing.**
- **Use medicines for fever**
- **Do not allow anyone to smoke around your child.**
- **If your child's breathing gets worse, take him or her outside in the cool air for 15-20 minutes. You can also try to create a heavy mist by taking him or her into the bathroom, closing the door and turning on the hot shower to make the room misty. Do not place your child in the hot shower; just hold him or her in the room.**

Call or return immediately for the following:

- **Increased difficulty breathing or swallowing.**
- **Excessive drooling**
- **A blue color around the mouth or fingernails**
- **Increased restlessness or exhaustion.**

Call your doctor for the following:

- **For follow-up as directed.**
- **For any other questions or concerns.**

Case 2

18 mo with sudden onset of vigorous coughing followed by stridor and drooling

Croup – what else could it be?

- Spasmodic croup (recurrent croup)
- Retropharyngeal abscess
- Subglottic stenosis
- Angioedema
- Allergic reaction
- Tracheomalacia
- Laryngeal web
- Laryngeal papillomatosis
- Laryngeal hemangioma
- Subglottic hemangioma
- Vocal cord paralysis
- Uvulitis
- Innominate artery compression
- Right aortic arch vascular ring
- Double aortic arch
- Aberrant subclavian artery
- Pulmonary artery sling
- Gastroesophageal reflux (diagnostic consideration for recurrent croup)

- Airway Foreign Body
- Esophageal Foreign Body
- Bacterial Tracheitis
- Diphtheria
- Epiglottitis
- Inhalation Injury
- Laryngeal Fractures
- Laryngomalacia
- Measles
- Mononucleosis and Epstein-Barr Virus Infection
- Peritonsillar Abscess
- Rarer etiologies in the pediatric population - Laryngeal tuberculosis, neoplasm (compressing trachea), sarcoidosis, Wegener granulomatosis

Foreign Body Aspiration

- Airway versus esophageal

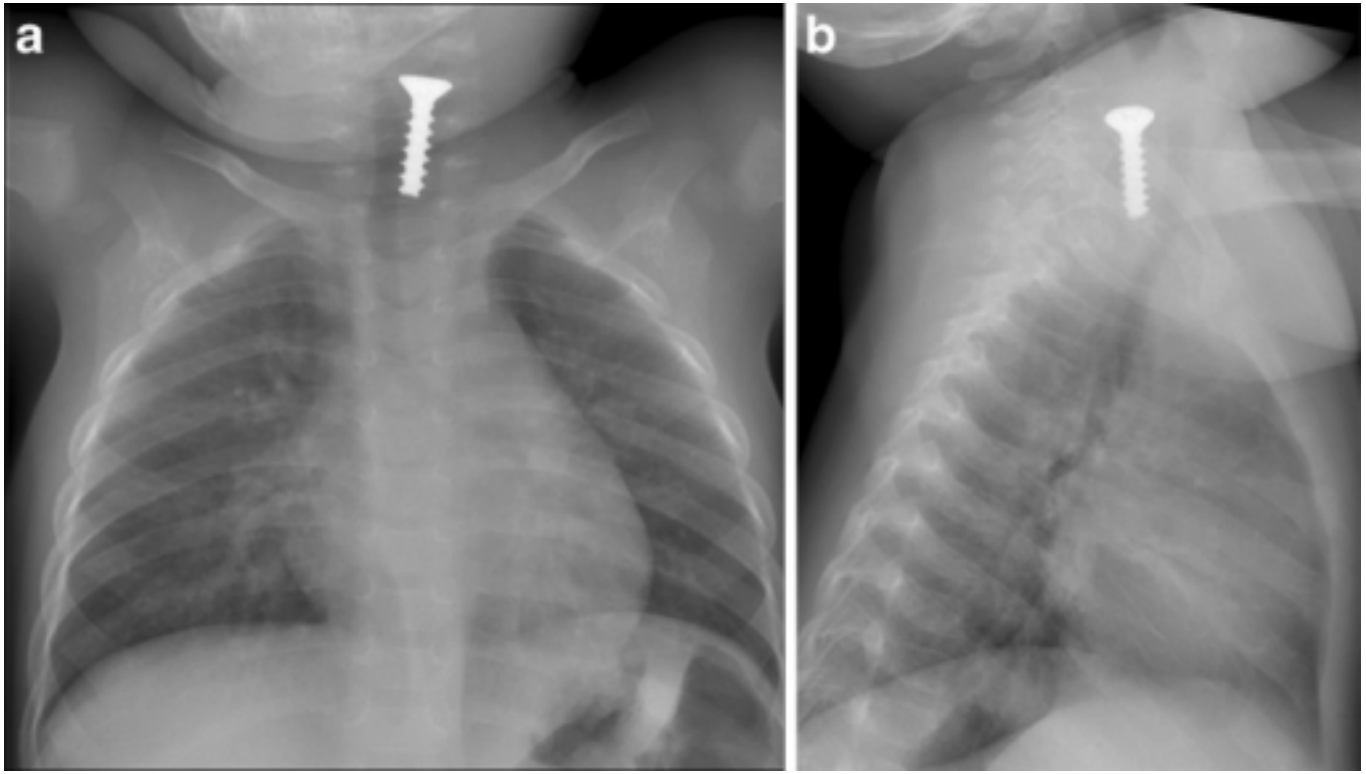

Foreign Body Aspiration

- Inspiratory and expiratory films

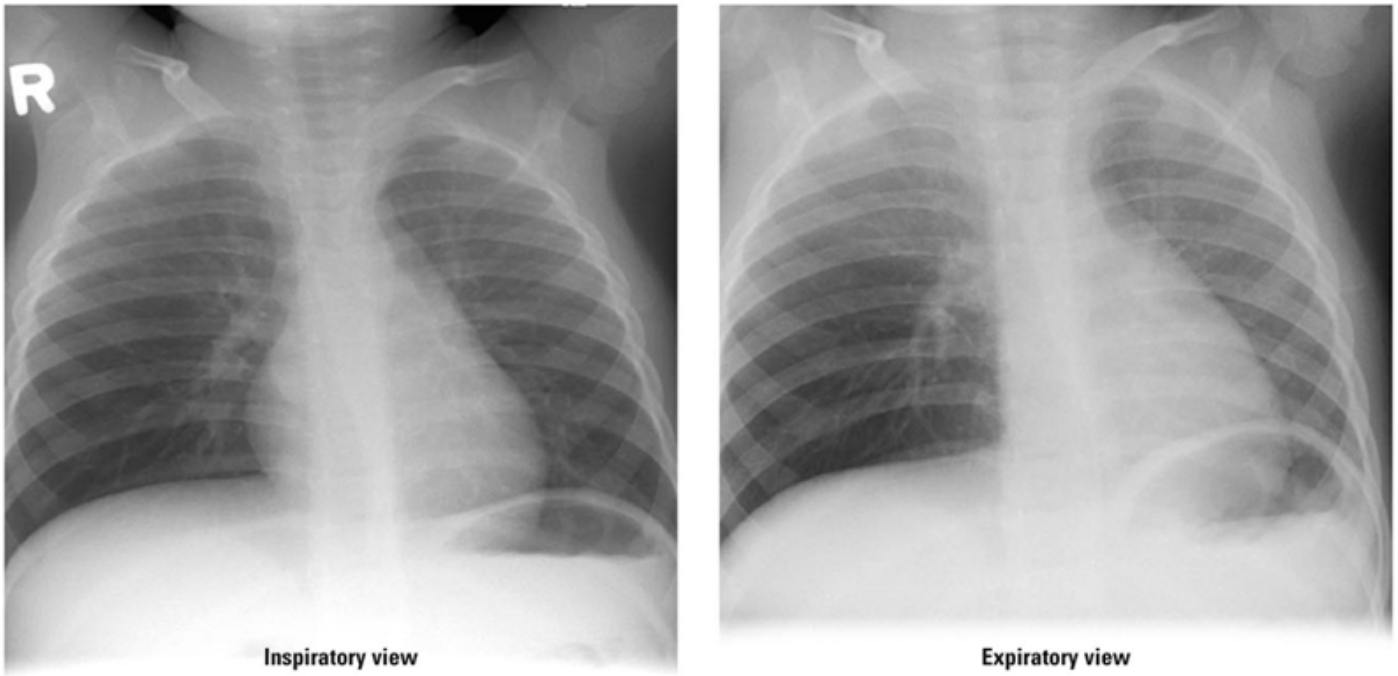

Figure 1. Right-sided air trapping (i.e., obstructive emphysema) due to partial obstruction (check valve) of the right main bronchus. The left side deflates during expiration but the right side cannot deflate. Mediastinum shifts toward the unobstructed side. When obstruction becomes complete, then complications such as pneumonia or atelectasis can ensue.

Foreign Body Aspiration

- Upright and decubitus films

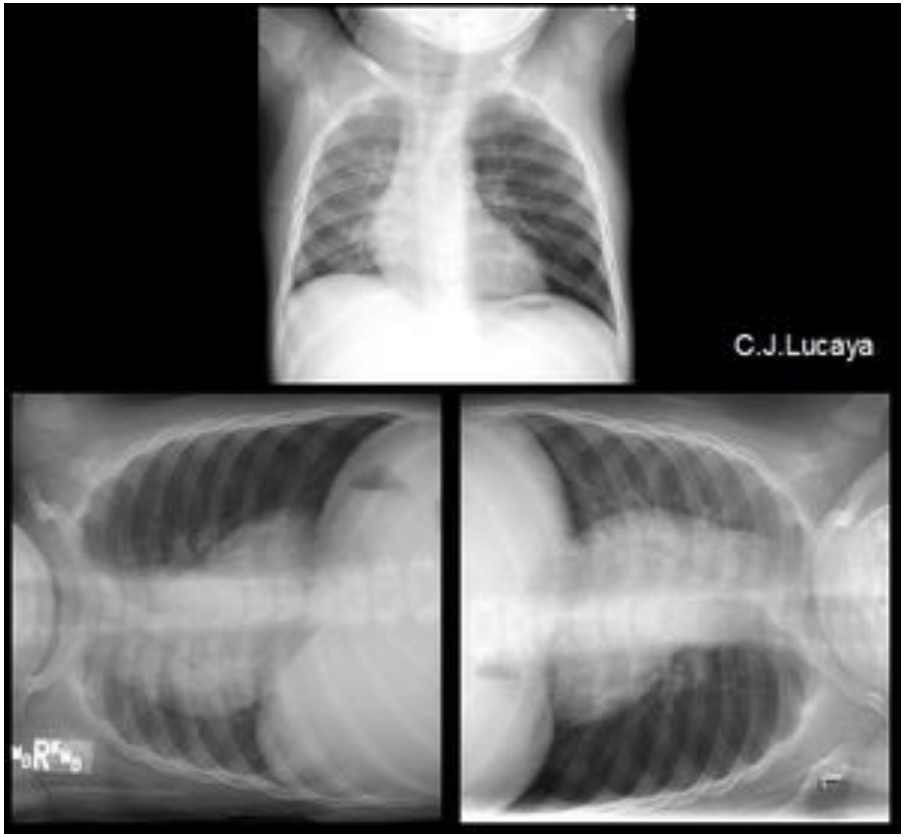

Foreign Body Aspiration

- An estimated 1,908 ± 273 pediatric bronchial FBA patients were admitted annually over the 3-year period from 2009-2012 (mean age, 3.6 ± 0.3 years; 61.3% ± 1.9% male).
- The ratio of foreign object aspiration to food aspiration was 5:3.
- Overall, 56%.0 ± 3.6% of the patients underwent a bronchoscopic procedure for foreign body removal; of those, 41.5% ± 2.5% had a foreign body removed at the time of the endoscopy.
- The hospital mortality rate associated with bronchial aspiration was 1.8% ± 0.4%; and 2.2% ± 0.5% of patients were diagnosed with anoxic brain injury.
- The median length of stay was 3 days (25th-75th interquartile range, 1-7 days).
- The median charges and actual costs per case were $20,820 ($10,800-$53,453) and $6,720 ($3,628-$16,723), respectively.

Kim et al, Laryngoscopy 2014

Foreign Body Aspiration

presenting symptoms

From 210 cases taken to the OR over 8 years at one institution with 130 having FB discovered. Only 5 of the FBs were non-food items.

Table 2
Appreciation factors

Appreciation factors	Positive bronchoscopy		Negative bronchoscopy	
	No. cases	Frequency of symptoms (%)	No. cases	Frequency of symptoms (%)
Suffocation history	119	91.5	35	43.7
Cough	107	82.3	37	46.2
Dyspnea	32	24.6	12	15
Cyanosis	7	5.3	0	0
Apnea	2	1.5	0	0
Diminish of breath sounds	76	58.4	20	25
Inspiration stridor	15	11.5	1	0.7
Atypical sounds	36	27.6	25	31.2
Fever	18	13.8	36	45
Respiratory infections	0	0	10	12
Emphysema	51	39.2	7	8.7
Atelectasis	12	9.2	9	11.2
Parenchyma densities	0	0	19	23.7

Skoulakis et al, Int J Pediat Otorhinolar 2000

Patients. —All children (n=165) who underwent endoscopy for foreign body aspiration or ingestion at Children's Hospital of Pittsburgh (Pa) between 1989 and 1993 and children (n=449) whose deaths due to choking on man-made objects were recorded by the Consumer Product Safety Commission (CPSC) between 1972 and 1992.

Main Outcome Measures. —Objects removed from children's aerodigestive tracts were characterized by location, procedure for removal, and type. Objects causing death were characterized by type, shape, and consistency. Three-dimensional objects that had caused asphyxiation were analyzed by computer-simulated models.

Results. —Of the 165 children treated by endoscopy, 69% were 3 years of age or younger. Foreign bodies most often ingested or aspirated were food (in 36 children) and coins (in 60 children). Of 449 children whose deaths after aspirating foreign bodies were reported to the CPSC, 65% were younger than 3 years. Balloons caused 29% of deaths overall. Conforming objects such as balloons caused a significantly ($P<.01$) higher proportion of deaths in those aged 3 years or older (60%) vs those younger than 3 years (33%). Of the 101 objects causing deaths that we could analyze, 14 met current standards for use by children younger than 3 years.

Conclusions. —Balloons pose a high risk of asphyxiation to children of any age. Changes in regulations regarding products intended for children's use might have prevented up to 14 (14%) of 101 deaths in this study.(*JAMA*. 1995;274:1763-1766)

Case 3

4 y.o. with runny nose and barky cough for 3 days in the last 12 hours seems much more ill and has stridor

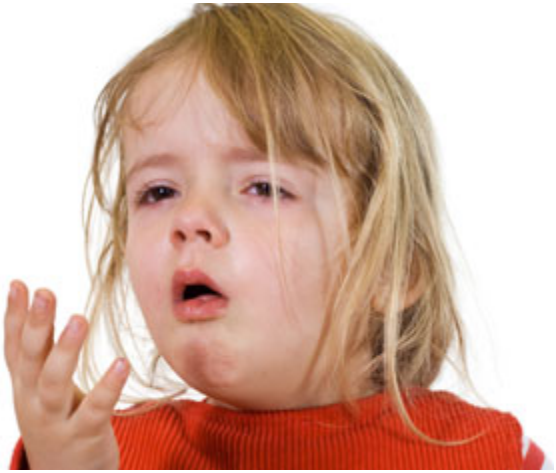

Croup – what else could it be?

- Spasmodic croup (recurrent croup)
- Retropharyngeal abscess
- Subglottic stenosis
- Angioedema
- Allergic reaction
- Tracheomalacia
- Laryngeal web
- Laryngeal papillomatosis
- Laryngeal hemangioma
- Subglottic hemangioma
- Vocal cord paralysis
- Uvulitis
- Innominate artery compression
- Right aortic arch vascular ring
- Double aortic arch
- Aberrant subclavian artery
- Pulmonary artery sling
- Gastroesophageal reflux (diagnostic consideration for recurrent croup)
- Airway Foreign Body
- Esophageal Foreign Body
- **Bacterial Tracheitis**
- Diphtheria
- Epiglottitis
- Inhalation Injury
- Laryngeal Fractures
- Laryngomalacia
- Measles
- Mononucleosis and Epstein-Barr Virus Infection
- Peritonsillar Abscess
- Rarer etiologies in the pediatric population - Laryngeal tuberculosis, neoplasm (compressing trachea), sarcoidosis, Wegener granulomatosis

Bacterial Tracheitis

- An uncommon infectious cause of acute upper airway obstruction
- Patients may present with croup-like symptoms, but do not respond to standard croup therapy (racemic epinephrine)
- Although the pathogenesis is unclear, mucosal damage or impairment of local immune mechanisms due to a preceding viral infection, an injury to trachea from recent intubation, or trauma may predispose the airway to invasive infection with common pyogenic organisms.
- A diffuse inflammatory process of the larynx, trachea, and bronchi with adherent or semi-adherent mucopurulent membranes within the trachea.
- The major site of disease is at the cricoid cartilage level, the narrowest part of the trachea.
- Acute airway obstruction may develop secondary to subglottic edema and sloughing of epithelial lining or accumulation of mucopurulent membrane within the trachea.
- May be more common in the pediatric patient because of the size and shape of the subglottic airway. In this smaller airway, relatively little edema can significantly reduce the diameter of the pediatric airway, increasing resistance to airflow and work of breathing.

Tracheal size and swelling

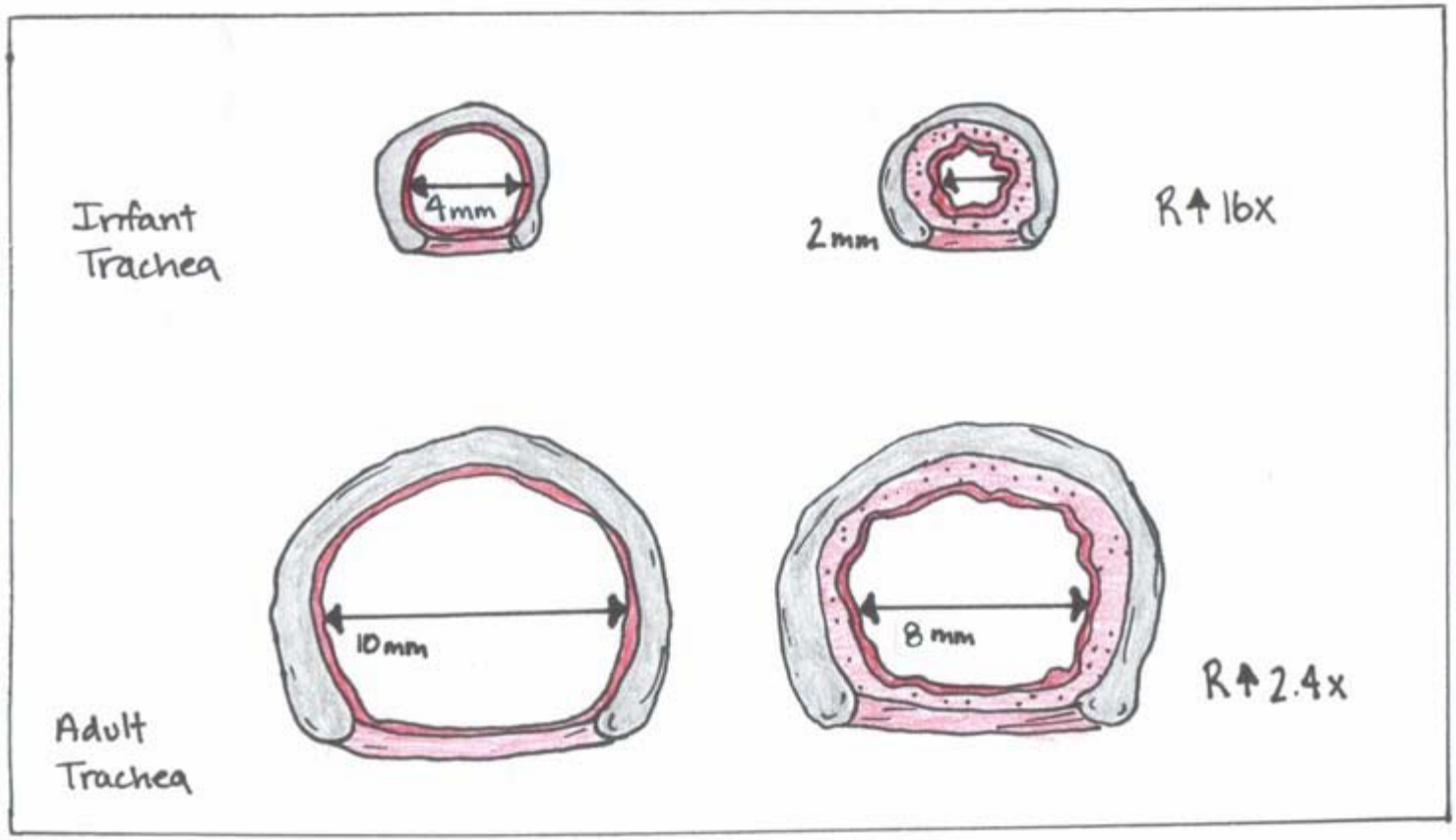

Bacterial Tracheitis – history and PE

- Presentation is either acute or sub-acute.
- The prodrome is usually an upper respiratory infection, followed by progression to higher fever, cough, inspiratory stridor, and a variable degree of respiratory distress.
- In the classic presentation patients present acutely with fevers, toxic appearance, stridor, dysphonia, tachypnea, respiratory distress, and high WBC counts. Cough is frequent and not painful in chest but may hurt in throat.
- Anecdotally, often c/o sore throat out of proportion to usual
- older children (mean age, 8 y) tend to have less severe clinical symptoms.
- Patients may acutely decompensate with worsening respiratory distress due to airway obstruction from a purulent membrane that has loosened.
- A high index of suspicion for bacterial tracheitis is needed in children with viral croup–like symptoms who do not respond to standard croup treatment or clinically worsen.

Bacterial Tracheitis – Work-up

- Airway x-rays with subglottic edema and possible membrane
- Definitive diagnosis best made in the OR during rigid bronchoscopy

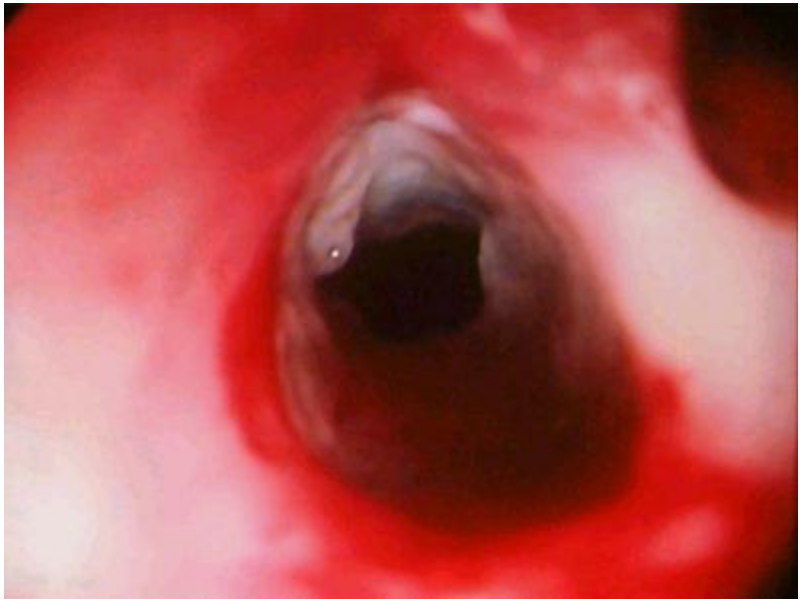

Bacterial Tracheitis - Etiology

- *S aureus:* Community-associated methicillin-resistant *S aureus* (CA-MRSA) has recently emerged as an important agent in the United States; this could result in a greater frequency of MRSA strains that cause tracheitis.
- *S pyogenes, Streptococcus pneumoniae,* and other alpha hemolytic streptococcal species
- *Moraxella catarrhalis* is a leading cause of bacterial tracheitis and associated with increased intubation.
- *Haemophilus influenzae* type B (Hib): This cause is less common since the introduction of the Hib vaccine.
- *Klebsiella* species, *Pseudomonas* species, Anaerobes, p*eptostreptococcus* species, *Bacteroides* species, *Prevotella* species, and *Mycoplasma pneumoniae*
- *Mycobacterium tuberculosis* (endobronchial disease)
- H1N1 influenza

Bacterial Tracheitis - Treatment

- Airway Maintenance of an adequate airway is of primary importance.
- Avoid agitating the child. If the patient's respiratory status deteriorates, it is usually because of movement of the membrane, and bag-valve-mask ventilation should be effective.
- If intubation is required, use an endotracheal tube 0.5-1 size smaller than expected in order to minimize trauma in the inflamed subglottic area. Frequent suctioning and high air humidity is necessary to maintain endotracheal tube patency; therefore, use the most appropriate-sized tube (without causing trauma). Most patients (57-100%) require eventual intubation.
- Intravenous access and medication
- Antibiotic regimens have traditionally included a third-generation cephalosporin (eg, cefotaxime, ceftriaxone) and a penicillinase-resistant penicillin (eg, oxacillin, nafcillin) or clindamycin. Vancomycin should be started in patients who appear toxic or have multiorgan involvement or if MRSA is prevalent in the community.

The End…….

but I am <u>happy</u> to take more questions?



Airway anatomy……. from an intubator's point of view